

Placental histomorphology and morphometry in the pregnant mice treated with cell phone radiation

Ali Louei Monfared^{1*}, Aaref Nooraii², Morteza Shamsi^{3,4}

1. Department of Basic Sciences, Faculty of Para-Veterinary Medicine, University of Ilam, Ilam, Iran
2. Department of Basic Sciences, Faculty of Para-Veterinary Medicine, University of Urmia, Urmia, Iran
3. Clinical Microbiology Research Center, Ilam University of Medical Sciences, Ilam, Iran
4. Department of Biology, Payame Noor University, PO BOX 19395-4697 Tehran, Iran

***Corresponding author:** Tel: +98 2224308 Fax: +98 2224308

Address: Department of Basic Sciences, Faculty of Para-Veterinary Medicine, University of Ilam, Ilam, Iran

E-mail: alm722@gmail.com

Received; 2015/08/12 revised; 2015/08/31 accepted; 2015/10/5

Abstract

Introduction: The use of cell phones is widespread and there are public concerns regarding its possible deleterious effects on human health especially on the pregnancy outcomes. In this study, structural changes of the placenta after applying the cell phone radiation were examined in the mice model.

Materials and methods: For this work, 40 pregnant Balb/C mice were randomly allocated to one control and one experiment groups. The experimental animals were exposed to cell phone fields with a carrier frequency of 915 MHz, for 4 h a day continuously, during 5-17 days of gestation. On the 18th day of pregnancy, the half of each groups were sacrificed and placentas specimens were taken for histological studies. In the rest of animals, the neonates were counted and the offspring's survival rates were determined. Also, morphometrical aspects of the placentas were studied.

Results: There were no morphometric as well as light microscopic changes in the placentas between two groups. Ultrastructural results of the treated group revealed a slight elevation in the number of intra cytoplasmic droplets in the labyrinth interhemal membrane. In addition, in the electromagnetic fields (EMFs) exposed mice, the nucleus of the cytotrophoblast cells occasionally was large in the size and irregular in the shape and also had compact nucleoli. Finally, the survival rate of the neonate was not significantly affected by cell phone exposition.

Conclusion: according to the results of the present study, the cell phone radiation at 915 MHz may exert deleterious effects on the placenta in the mice model.

Keywords: Histomorphology, Placenta, Electromagnetic fields, Ultrastructure

Introduction

Placenta is an important organ which maintaining healthy pregnancy and linked mother with developing embryo for vital nutrient exchange (1). In fact, placenta serves to continuing materno-fetal interference by successful transport of essential nutrients and waste products between mother and embryo (2, 3). Furthermore, it is believed that appropriate

fetal growth is mainly dependent on the normal placental efficiency during pregnancy .

Over the last three decades, electromagnetic radiations equipment with various frequencies is commonly present in our home and occupational settings and also through cell phones systems (5, 6). Furthermore, the use of cell phones is

widespread and tele-communication systems increased the electromagnetic fields exposure (7). It has been shown that mobile phones are low power radio equipment that transporting radio frequencies in the microwave range of 900-1800 MHz through an antenna which used close to the user's head (8).

There are considerable public concerns about possible deleterious reproductive and developmental outcomes resulting from exposure to EMFs. Many of the experimental health investigations have been showed some evidence of increased risk of adverse bio-effects contributed to the EMFs radiation. For instance, previous researchers found an increase in the serum levels of LH but no alteration in the serum concentration of FSH in the rats after electromagnetic radiations exposure at 2.8 GHz and 100 Watts/m² (6, 9). Also, it had been reported that EMFs exposure with various frequency and intensity caused a significant higher increase in the plasma testosterone concentration in the rat (7), DNA strand breaks or nerve cell damage (10,11), induction of oxidative stress in the rat brain tissue (12,13), and also ovarian dysfunction during pregnancy (14, 15).

In contrast, with the above mentioned literature, several authors failed to find any side effect for EMFs exposure regarding histo-pathological and physiological parameters of the various body organs including placenta, ovary, uterus and testes (16-19). Additionally, it is speculate that gestational exposure of the pregnant rats to different ranges of EMFs did not produce any fetal development and reproduction rate (18, 20, 21), embryonic development (22), as well as the utero-placental blood circulation (14).

As above mentioned, the relevant literature provides diverse data; while some studies demonstrates detrimental effects of EMFs exposure on the various body organs, other conclude that EMFs treatment could not affect fetal development and as well as the placental efficacy. It is possible that the different outcomes may be resulted from

the diverse experimental protocols and different equipment and as well as intensity of the applied EMFs (23). On the other hands, there are limited investigations on the placental toxicity after EMFs exposition. Therefore, this study aims to investigate the probable histo-morphological and morphometrical alterations of the placenta after exposure to cell phone radiation in the mice model.

Materials and methods

Animal preparation: Experimental studies were carried out in accordance with institutional ethic protocols for animal husbandry in the University of Ilam. Additionally, during the exposure period animals had free access to food and drinking water .

For this work, 40 male and 40 female Balb/C mice, 8 to 9 weeks-old were purchased from laboratory animal's center at Ilam University (Ilam, Iran). Mating was carried out by overnight pairing of one female and one male overnight. Then, appearance of a vaginal copulatory plug was detected as Day 0 gestation. The pregnant animals were randomly allocated to one control and one experiment groups . The experiment group (n = 20) was exposed to radiofrequency electromagnetic field from four mobile phones (Nokia 1208 model), which operates with microwave carrier frequencies in the range 915 MHZ (7, 24). The exposure time was from 8:00 am to 12:00 noon for 13 days during 5th to 17th day of gestation. The treatment was done in special plastic cages, the cell phone being placed under the cage at a distance 0.5 cm below the undersurface of the cage (25), and the cell phones were kept in the talking mode, receiving calls from another phones during hours of EMF exposure, but in silent mode, during the whole time of exposure. Control group of animals (n = 20) was kept under similar environmental conditions, but they exposed to mobile phones system without battery and lack of electromagnetic source.

Histo-morphological, morphometrical and ultra-structural evaluations: The half of animals ($n = 10$) in each group were anesthetized on the 18th day of pregnancy and their abdomen cavity was opened and their fetoplacental units were removed from the uterus. For gross study; the collected placentas were weighted by electronic scale and also then the weight of births and also the ratio of placental to birth weights were determined. In addition, a caliper was used for determining the diameter and thickness of the placentas. For histological assay, the specimens were fixed in the formalin 10%; then sectioned by microtome at 6 μ m and mounted on the glassy slides. The prepared slides were stained with hematoxylin-eosin method and characterized using a light microscope and then analyzed using a digital camera. In all groups, the number of the placenta's cells per five microscopic fields was manually counted. Furthermore, the proportion of different placental area was compared between two groups by computed image analysis (UTHSCSA, San Antonio, TX, USA). For ultra-structural assay; the specimens were fixed in the 2.5% glutaraldehyde and post fixed with 1% osmium tetroxide in phosphate-buffered saline for 2 hours. Dehydration stage was carried out by using ascending dilutions of ethanol. Then specimens placed in the propylene oxide and embedded in the Epon 812. Semi-thin sections were stained with toluidine blue for studying under light microscopy and then 60-80 nm sectioned samples were stained by uranyl acetate and lead citrate. Finally, structural sections were examined under transmission electron microscopy (Zeiss 902, Germany).

Determination of the rate of neonate's survival: In the rest of the animals ($n = 10$), after delivery, the number of the neonates was counted in each group. Neonatal mortality rate were estimated within days 5, 10, 15, and 20 after birth according to the following formula: living neonates count/ dead neonates count (26). Data analysis and statistics: Computational statistics of the results were performed by using SPSS software and all data were demonstrated as mean \pm standard error. In addition, for homogeneity of variance assay; data were analyzed by using Bartlett's test. For quantitative items; two-sample t-test assuming equal variance and unequal sizes was carried out to compare the values between control and experiment groups. Also, a non-parametric Kruskal-Wallis test was performed, if the homogeneity of variance was rejected.

Results

Morphological observations: On the placental morphology; there was not any difference between EMFs exposed or control group. In the cell phone treated mice there are no significant alterations in the mean of the placental weights, the ration of the placental to fetal weights and also the fetal weight in comparison with unexposed animals (Table 1). Similarly, the means of the thickness and diameter of the placentas were not affected by electromagnetic waves of the cell phones exposure, when compared with control animals (Table 1). In addition, there was no external, visceral, and skeletal malformation or anomalies in both control and cell phone treated mice. Also, among pregnant mice in the EMFs exposed or control group no abortion occurred.

Table 1. Effects of the cell phone radiation on the gross parameters of the placenta during 5th to 17th days of gestation.

Parameters/ Groups	Control	Cell phone exposed
Placental weight (g)	0.46 \pm 0.07 *	0.48 \pm 0.09
Placental: fetal weight ratio (%)	11.3	11.5
Fetal weight (g)	4.57 \pm 0.04	4.63 \pm 0.09
Placental thickness (mm)	0.13 \pm 0.01	0.12 \pm 0.04
Placental diameter (mm)	10.9 \pm 0.04	11.2 \pm 0.03

Light microscopic observations: Histological studies of placentas from EMFs exposed or control group are shown in the figures 1 to 3. Based on the light microscopic studies, cell phone exposure could not alter the proportions of the decidua zone as well as junctional zone per whole placenta. In addition, the area of the labyrinth per whole placenta revealed a normal structure in the both cell phone exposed as well as unexposed groups (Figure 1). At higher magnification, the

number and size of the spongiotrophoblast cells as well as glycogen cells were not found to be different between two groups (Figure 2). In addition, at higher magnification, an abundant network of fetal capillaries was developed in the near side of the maternal vessels sinuses in both control and cell phone exposed placentas (Figure 3). More detailed analysis of placental tissue confirmed above mentioned observations.

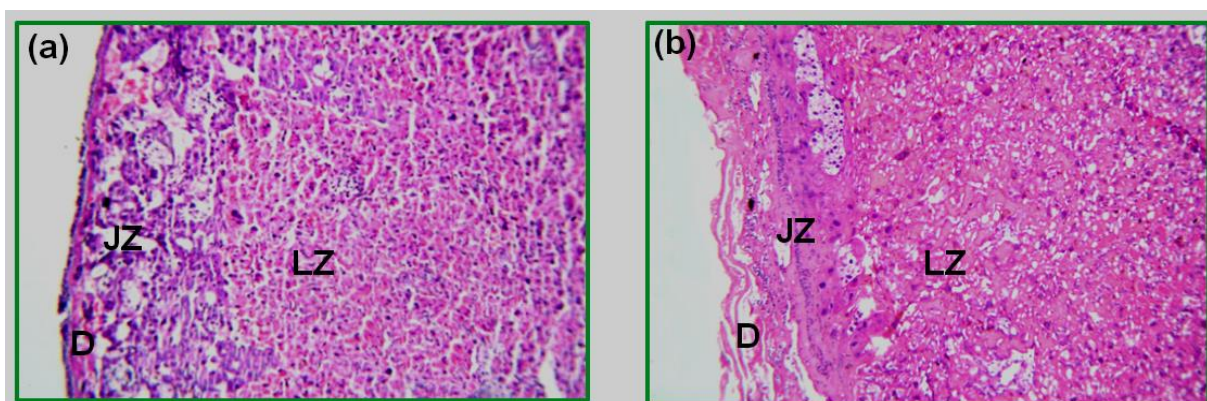


Figure 1. (a) Light micrographs of the placenta showing normal histological structure in the control group. (b) Light micrographs of placenta in the EMFs exposed animals. This figure represented the normal proportions of the decidua zone (D) as well as junctional zone (JZ) per whole placenta. In addition, these figures demonstrate the normal size of labyrinth zone membrane (LZ) per whole placenta in the EMFs exposed mice when compared with controls. (Haematoxylin and eosine stain) (Magnification: $\times 100$ a, b).

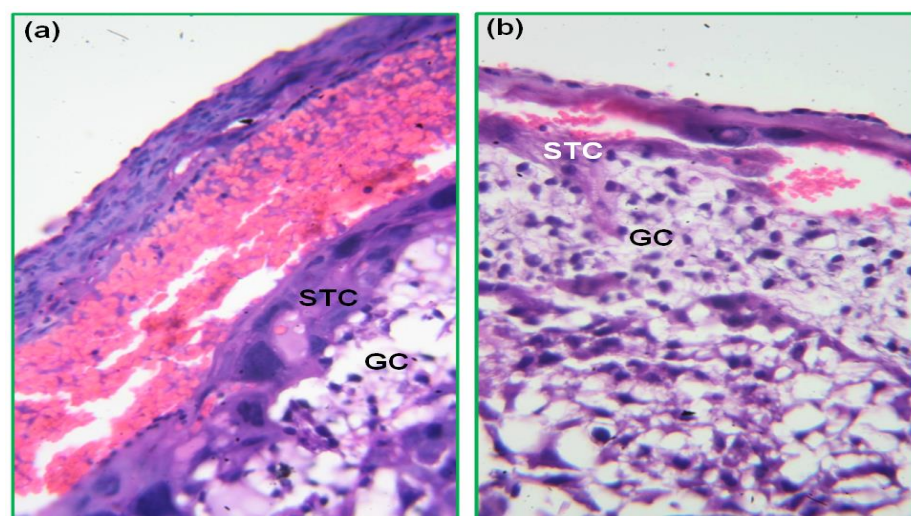


Figure 2. (a) Higher magnification of figure 1-a; shows placental junctional zone in control group. Note the normal sizes and numbers of the spongiotrophoblast cells (STC) or glycogen cells (GC). (b) Higher magnification of figure 1-b; shows placental junctional zone in the EMFs exposed group. The figure demonstrates that the numbers and sizes of the spongiotrophoblast cells (STC) or glycogen cells (GC) were not affected by cell phone radiation. (Haematoxylin and eosine stain) (Magnification: $\times 400$ a, b).

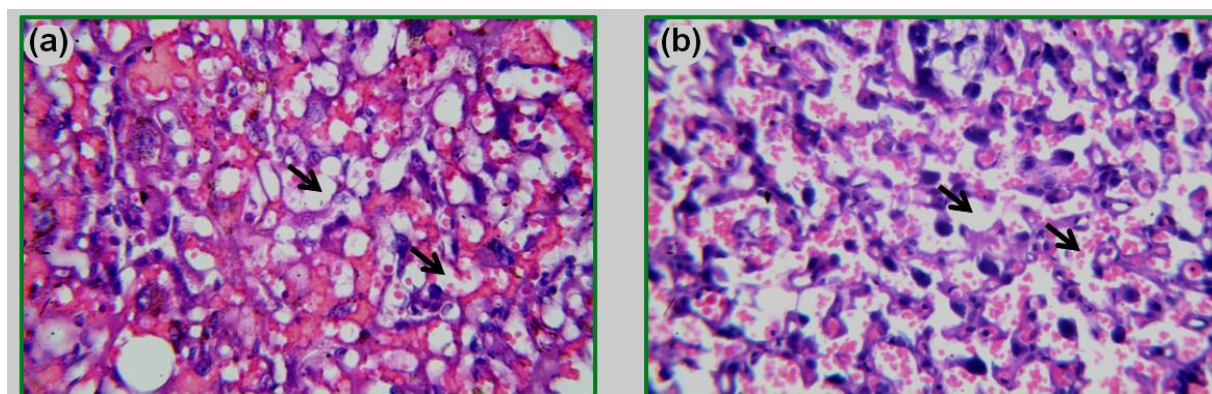


Figure 3. (a) Higher magnification of figure 1-a; showing placental labyrinth membrane in control animals. Note the abundant network of fetal capillaries (arrows) development in the near side of the maternal vessels sinuses. (b) Higher magnification of figure 1-b; shows transverse section through labyrinthine zone of the placenta in the cell phone exposed group. The figure reveals that maternal as well as fetal blood vessels (arrows) are present in normal structure. (Haematoxylin and eosine stain) (Magnification: $\times 400$ a, b).

Electron microscopic observations: In the electron microscopy fields belonging to cell phone exposed placentas, there was a slight elevation in the number of small droplets inside the cytoplasm of trophoblast layers 2 and 3 of the labyrinth interhemal membrane (Figure 4b). However, the number of these droplets were normally little in the placentas from control animals (Figure 4a). In addition, there was not found any significant changes between two groups regarding the thickness of the basement membrane between cytotrophoblaste and fetal endothelial capillaries (Figure 4a and 4b). Similarly, basement membranes thickness (BMT) of trophoblastic layers and also the diameter of the labyrinth zone membrane (LZM) were compared between EMFs exposed or control groups. At higher

resolution, neither TBM thickness nor the diameter of the placental LIM was significantly different between cell phone exposed and control mice (Figure 4a and 4b) (Table 2). In agreement with previous in the light microscopic results, the number of blood vessels not altered in the cell phone exposed group (Figure 5). However, the nucleus of the cytotrophoblast cells occasionally was large in the size and irregular in the shape and also had compact nucleoli, when compared with regular and electron-lucent eu-chromatin nucleus of the control group (Figure 5).

Survival rates of the neonate's mice: The number of the neonates in the cell phone exposed mice was not significantly altered on the days 5, 10, 15, and 20 after birth when compared with control group.

Table 2. Effects of the cell phone radiation on the ultrastructure of the labyrinth membrane during 5th to 17th days of gestation.

Parameters/Groups	Control	Cell phone exposed
Thickness of the TBM (nm)	6.3 ± 0.18	6.2 ± 0.08
Diameter of the LIM (μm)	84.7 ± 6.1	83.9 ± 4.8

Aababbreviations: LIM; labyrinth interhemal membrane, TBM; trophoblastic basement membranes.

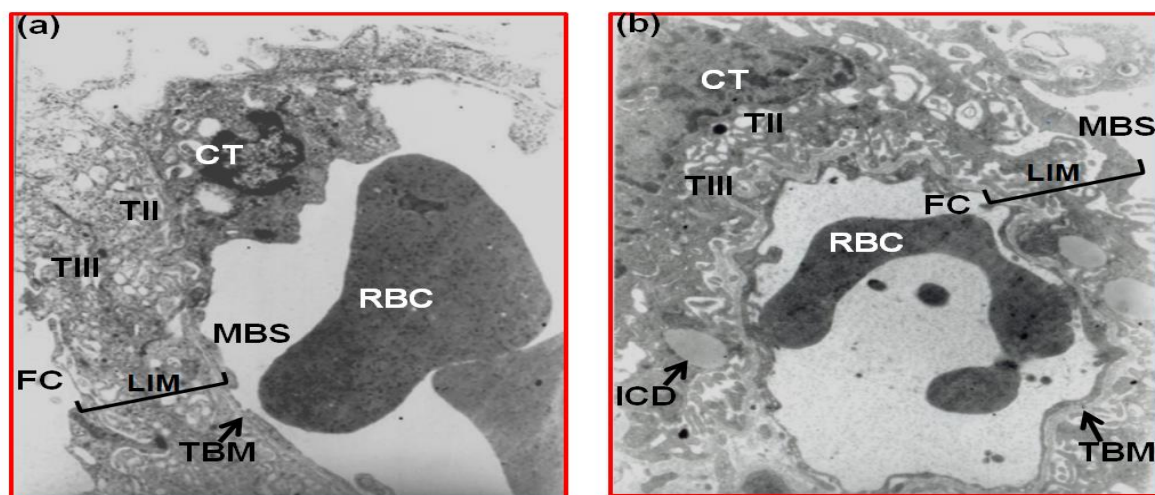


Figure 4. (a) Transmission electron micrographs through placental labyrinthine membrane in the control group. The labyrinth interhemal membrane (LIM) is marked by brackets. This part shows normal ultrastructures of the trophoblastic layers II and III of LIM. Also, the diameter of the LIM is normal. Furthermore, this figure demonstrates the standard thin thickness of the basement membrane (TBM) between cytotrophoblastic layer III and fetal endothelial capillaries. (b) Electron micrographs of the labyrinthine membrane of the placenta in the cell phone exposed group. The figure reveals that the diameter of the LIM and also the thickness of the TBM are present in normal status. Furthermore, a slight elevation in the number of small droplets inside the cytoplasm (ICD) of the trophoblast layers 2 and 3 of the LIM are noticeable. (Magnification : $\times 7000$ a , b). (CT); cytotrophoblastic cells, (FC); fetal capillary, (MBS); maternal blood sinuses, (RBC); red blood cells, (TII); the second trophoblastic layer, (TIII); the third trophoblastic layer.

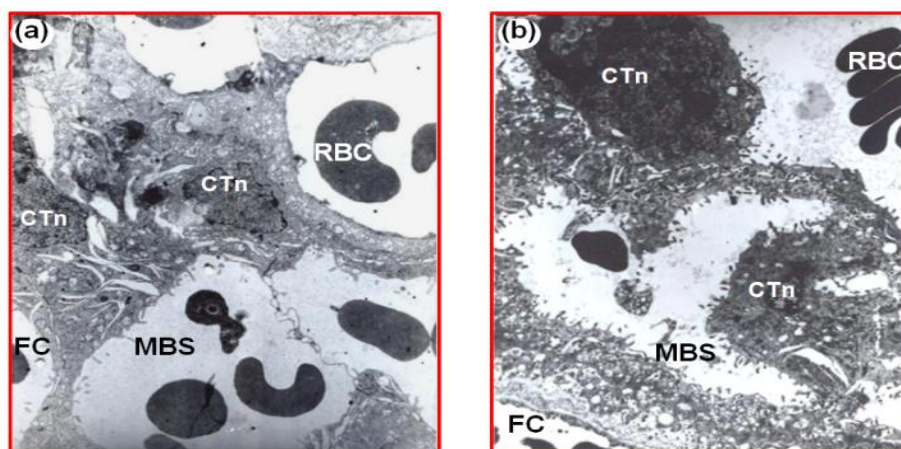


Figure 5. (a) Electron micrographs of the labyrinthine membrane of the placenta in the control animals; showing standard ultrastructure of the fetal capillaries (FC) developed in the near side of maternal blood sinuses (MBS). Furthermore, this figure demonstrates regular and electron-lucent euchromatin nucleus of the cytotrophoblast cells (CTn). (b) Transmission electron micrographs through the labyrinthine zone of the placenta in the cell phone exposed group. Note normal ultrastructures of the FC development in the juxtaposition to MBS. In addition, in this figure the altered shape and heterochromatin of the nucleus of the cytotrophoblast cells (CTn) is noticeable. (Magnification: $\times 4500$ a , b). (RBC); red blood cells.

Discussion

It is well established that toxic foreign compounds could impact on the placental tissue at many levels, and any pathological output may be leads to a potential threat to utero-placental unit, resulting in abortion, birth defects or congenital abnormalities

(27). In addition, research on the placental histo-anatomy and its probable relations to fetal growth is crucial; because of abnormal intrauterine conditions may predispose the birth to establish abnormal status in the adult life (28). This study

aims to investigate the probable histomorphological and morphometrical alterations of the placenta after exposure to EMFs. For this purpose, the cell phone radiation period was extended to day 17 of gestation. However, present endpoints do not support this hypothesis that cell phone exposition during pregnancy could produce any toxicological alterations in the placental tissue as well as morphometric parameters and also in the survival rates of the neonate. Overall, both light and electron microscopy examinations of the placentas which receiving electromagnetic radiation clearly demonstrated no major structural changes when compared with controls. In accordance with present findings, Liaginskaia et al. [2010] studied the effects of intraperitoneally injection of blood serum obtained from EMFs exposed rats on the pregnancy output. Their results show no any toxic changes in terms of placental weight or dimensions and also embryo weights (29). Similarly, Chung et al. [2003] reported that cell phone exposition during rat's pregnancy has not any toxic impacts on the feto-placental development, placental weight and also body weight alterations (18).

Another study also showed that EMFs treatment at 50 Hz during organogenesis period in the rat's model has not any side effects on the fertility and also utero-placental structure (22). Additionally, no exposure-related changes in the feto-placental histology, incidence of fetal malformations or anomalies and fetal viability as well as body weight were found in the previous study (20); that in which pregnant Sprague-Dawley rats were exposed to 60 Hz power frequency magnetic fields at strengths of 0.2 or 1 mT (2 or 10 G), for 18.5 hours/day, during gestation days 6 to 19.

The effects of electromagnetic fields radiation on the structure and physiology of the whole placenta has been studied by Huuskonen et al. [1993] (21). Their findings show that continuous exposure to EMFs at 50-Hz during days 0 to 20 of

gestation did not induce developmental alterations on the fetal development. In addition, Nakamura et al. [2003] failed to show any placental or fetal blood insufficiency as well as reproductive hormones concentrations after exposure of pregnant rats to the cell phone frequency microwaves at 915 MHz, 0.6 m Watts/cm² (14). The above-discussed studies are in line with present morphometric findings.

In the present study, the lack of any structural changes in the EMFs treated placental tissue which is in accordance with previous studies (14,16,17), reveals that the applied cell phone radiation established only some fine ultra-structural alterations, which are not pathologically significant.

Alternatively, it has been demonstrated that the close apposition of feto-maternal blood capillaries, has an important role in the normal transport of essential nutrients and waste products in the labyrinth membrane of the rodent's placenta (3). In addition, one of the critical items for normal physiology and functions of the placenta is appropriate size and diameter of labyrinth membrane (4). Thus, present results on the normal diameter of the labyrinth membrane and also the normal thickening of the TBM in the placentas of EMFs-treated animals, confirming standard diffusion distance between fetal and maternal blood supply. This basic structural integrity could be results in normal transports of essential nutrients between feto-maternal unit and thereby normal endpoints in birth development and weight (30, 31). It seems the above-mentioned observations are responsible for the normal neonate's survival rate endpoints, which obtained in the present study.

In the EMFs received animals, there was found a slight elevation in the number of small droplets inside the cytoplasm of trophoblast layers 2 and 3 of the labyrinth interhemal membrane (Figure 4-b). Literature review shows that such droplets basically contains nutrients, oxygen or

waste products and are found in the mouse's placenta in a normal pattern(4) . Although mechanisms underlying placental toxicity in the case of EMFs exposure are not clear; but it has been suggested that the consequences of the endocrine or cellular changes of the placenta may be explained as different physiological alterations like decreased utero-placental blood flow and increased

progesterone or PGF2 α secretion (14). Further work is required to clarify the consequences of mobile phone treatment on the gestation outcome; especially placental integrity and neonatal health. Taking together, upon to this study, it is conclude that EMFs exposition with a carrier frequency of 915 MHz; during 5-17 days of pregnancy could not causes toxic alterations in the mouse's placenta.

References

1. Mardi K, Sharma J. Histopathological evaluation of placentas in IUGR pregnancies. *Ind J Pathol Microbiol.* 2003; 46(4):551-4.
2. Vogel P. The current molecular phylogeny of Eutherian mammals challenges previous interpretations of placental evolution. *Placenta.* 2005; 26 (8-9):591-6.
3. Adamson LS, Lu Y, Whiteley KJ, Holmyard D, Hemberger M, Pfarrer C, and Cross JC. Interactions between trophoblast cells and the maternal and fetal circulation in the mouse placenta. *Develop Biol.* 2002; 250(2): 358-373.
4. Coan PM, Ferguson-Smith AC, and Burton GJ. Developmental dynamics of the definitive mouse placenta assessed by stereology. *Biol Reprod.* 2004; 70(6): 1806-13.
5. Nakamura H, Nagase H, Ogino K, Hatta K, Matsuzaki I. Uteroplacental circulatory disturbance mediated by prostaglandin F2 α in rats exposed to microwaves. *Reprod Toxicol.* 2000; 14(3):235-240.
6. Mikolajczyk H. Biological effects of electromagnetic fields below 300 MHz (pregnancy, litter size and gonadotropic activity of the anterior pituitary gland). *Med Pract.* 1978; 29(2): 111-120.
7. Forgács Z, Somosy Z, Kubinyi G, Bakos J, Hudák A, Surján A, Thuróczy G. Effect of whole-body 1800MHz GSM-like microwave exposure on testicular steroidogenesis and histology in mice. *Reprod Toxicol.* 2006; 22(1):111-7 .
8. Narayanan SN, Kumar RS, Potu BK, Nayak S, Bhat PG, Mailankot M. Effect of radio-frequency electromagnetic radiations (RF-EMR) on passive avoidance behaviour and hippocampal morphology in Wistar rats. *Upsala J Med Sci.* 2010;115(2):91-6.
9. Wilson JD. Chapter 13. In: Isselbacher, et al., editors. *Harrison's Principles of Internal Medicine.* 1994; 13 th Edition.
10. Lai H, Singh NP. Single- and double-strand DNA breaks in rat brain cells after acute exposure to radiofrequency electromagnetic radiation. *Int J Rad Biol.* 1996; 69(4):513-521.
11. Salford LG, Brun AE, Eberhardt JL, Malmgren L, Persson BR. Nerve cell damage in mammalian brain after exposure to microwaves from GSM mobile phones. *Environ Health Perspect.* 2003; 111(7):881-3.
12. Demsia G, Vlastos D, Matthopoulos DP. Effect of 910-MHz electromagnetic field on rat bone marrow. *Sci World J.* 2004; 4(S2):48-54.
13. Ilhan A, Gurel A, Armutcu F, Kamisli S, Iraz M, Akyol O, et al. Gingko biloba prevents mobile phone-induced oxidative stress in rat brain. *Clin Chim Act.* 2004; 340(1-2):153-162.
14. Nakamura H, Matsuzaki I, Hatta K, Nobukuni Y, Kambayashi Y, Ogino K. Nonthermal effects of mobile-phone

- frequency microwaves on uteroplacental functions in pregnant rats. *Reprod Toxicol*. 2003; 17(3):321–6.
15. Nakamura H, Ohsu W, Nagase H, Okazawa T, Yoshida M, Okada A. Uterine circulatory dysfunction induced by whole-body vibration and its endocrine pathogenesis in the pregnant rat. *Eur J App Physiol Occu Physiol*. 1996; 72(4):292-6.
 16. Jensch RP. Behavioral teratologic studies using microwave radiation: is there an increased risk from exposure to cellular phone and microwave ovens? *Reprod Toxicol*. 1997; 11(4): 601-11.
 17. Jensch RP, Weinberg I, and Brent RL. Teratologic studies of prenatal exposure of rats to 915-MHz microwave radiation. *Rad Res*. 1982; 92(1): 160-171.
 18. Chung MK, Kim JC, Myung SH, and Lee DI. Developmental toxicity evaluation of ELF magnetic fields in Sprague-Dawley rats. *Bioelectromag*. 2003; 24(4):231-240.
 19. Tumkaya L, Kalkan Y, Bas O, Yilmaz A. Mobile phone radiation during pubertal development has no effect on testicular histology in rats. *Toxicol Indust Health*. Oct 9. 2013; [Epub ahead of print]
 20. Ryan BM, Jr EM, Johnson TR, Gauger JR, McCormick DL. Developmental toxicity study of 60 Hz (power frequency) magnetic fields in rats. *Teratol*. 1996; 54(2):73-83.
 21. Huuskonen H, Juutilainen J, Komulainen H. Effects of low-frequency magnetic fields on fetal development in rats. *Bioelectromag*. 1993; 14(3):205-213.
 22. Negishi T, Imai S, Itabashi M, Nishimura I, Sasano T. Studies of 50 Hz circularly polarized magnetic fields of up to 350 microT on reproduction and embryo-fetal development in rats: exposure during organogenesis or during preimplantation. *Bioelectromag*. 2002; 23(4):369-389.
 23. Brent RL. Reproductive and teratologic effects of low-frequency electromagnetic fields: a review of in vivo and in vitro studies using animal models. *Teratol*. 1999; 59(4):261-286.
 24. Peter AVT, Emilie VD and Michael HR (2007): Workgroup Report: Base Stations and Wireless Networks-Radiofrequency (RF) Exposures and Health Consequences. *Environmental Health Perspectives*; 115(3):416–424.
 25. Aksen F, Dasdag S, Akdag MZ, Askin and Dasdag MM (2004): The Effects of Whole Body Cell Phone Exposure on the T1 Relaxation Times and Trace Elements in the Serum of Rats. *Electromagnetic Biology and Medicine*; 23(1): 7 – 17.
 26. Tachibana T, Wakimoto Y, Nakamuta N, Phichitraslip T, Wakitani S, Kusakabe K, Hondo E, Kiso Y. Effects of bisphenol A (BPA) on placentation and survival of the neonates in mice. *J Reprod Develop*. 2007; 53(3): 509-14.
 27. Myllynen P, Pasanen M, and Pelkonen O. Human placenta: a human organ for developmental toxicology research and biomonitoring. *Placenta*. 2005; 26(5): 361-371.
 28. Sooranna SR, Oteng-ntim E, Meah R, Ryder TA and Bajoria R. Characterization of human placental explants: morphological, biochemical and physiological studies using first and third trimester placenta. *Hum Reprod*. 1999; 14(2): 536–541.
 29. Liaginskaia AM, Grigor'ev IuG, Osipov VA, Grigor'ev OA, and Shafirkin AV. [Autoimmune processes after long-term low-level exposure to electromagnetic fields (the results of an experiment). Part 5. Impact of the blood serum from rats exposed to low-level electromagnetic fields on pregnancy, foetus and offspring development of intact female rats]. *Rad biol, radio*. 2010; 50(1):28-36.

30. Laurie GP, Emma EF, Violeta D, Charles OB, Candace CJ, Hanqin L, et al. Striking changes in the structure and organization of rat fetal membranes precede parturition. *Biol Reprod.* 1992; 53(2): 321–338.
31. Masashi H, Chisato T, Masao N and Yasue O. Quantitative investigations of placental terminal villi in maternal diabetes mellitus by scanning and transmission electron microscopy. *Tohoku J Exp Med.* 1992; 167(4): 247–257.