

Fabrication of a Silicon Auricular Prosthesis Using a Digital Model: A Clinical Report

Azita Mazaheri Tehrani ¹ , Arash Zarbakhsh ¹ , Verishe Rastin ¹ , Hamed Karimi ¹  

¹ Prosthodontics Department, Faculty of Dentistry, Tehran Medical Sciences, Islamic Azad University, Tehran, Iran

Article Info

Article type:

Clinical report

Article History:

Received: Jan. 20, 2023

Accepted: Jun. 19, 2023

Published Online: Dec. 16, 2023

✉ Correspondence to:

Hamed karimi
Department of Prosthodontics,
Faculty of Dentistry, Azad
University of Medical Sciences,
Tehran, Iran

Tel: (+98) 2122537234

Fax: (+98) 2122537234

Email:

Hamed64karimi@gmail.com

ABSTRACT

Introduction: Body defects impact well-being, necessitating efficient prosthetic techniques. This report explores integrating CAD/CAM technology for auricular prostheses, emphasizing a digital approach.

Material & Methods: The plan involved irreversible hydrocolloid impressions, generating a digital resin model through an indirect scanner. Traditional molding and 3D printing combined for pattern formation. The mold's investment, fabrication, and coloring used intrinsic and extrinsic painting.

Results: CAD/CAM showcased enhanced compatibility and aesthetics. The digital resin model improved adaptability, streamlining production, and accelerating the wax try-in process. Patient satisfaction during follow-ups validated the prosthesis success.

Conclusion: Exploring auricular prosthesis advancements via digital technology, particularly the digital resin model, demonstrated transformative outcomes. This approach not only enhances adaptability and aesthetics but also expedites production, promising a seamless and time-efficient restoration of ear aesthetics for individuals.

Keywords: Additive Manufacturing, Prosthetics, Silicones, Acrylics, Biocompatible Adhesives

➤ How to cite this paper

Mazaheri Tehrani A, Zarbakhsh A, Rastin V, Karimi H. Fabrication of a Silicon Auricular Prosthesis Using a Digital Model: A Clinical Report. J Bas Res Med Sci. 2023; 10(3):78-85.

Introduction

The primary function of the external ear is to transmit sound waves into the auditory canal and provide an optimal environment for inner ear membranes. Loss of the outer ear can occur due to various factors, such as congenital conditions, trauma, or skin cancers (1). Ear prostheses offer both functional and aesthetic benefits and can eliminate the need for reconstructive surgery. In general, the use of silicone maxillofacial prostheses offers several advantages, including minimal or no surgery, a natural appearance, and a reduced time commitment for the patient. However, one notable drawback is the daily placement and removal of the prosthesis (2,3).

Computer-aided design/computer-aided manufacturing (CAD/CAM) technology has brought about a significant revolution in dental techniques and materials. There are two primary types of dental CAD/CAM scanners: intraoral (direct) scanners used chairside to scan patients' dental arches, and extraoral (indirect) scanners employed in dental laboratories for scanning (4). Unlike physical models produced using more traditional

prosthetic fabrication techniques, a digital representation of the missing structure can be created by mirroring the unaffected, contralateral side or utilizing the anatomical features of another individual. This approach results in a prosthesis that is more adaptable and aesthetically pleasing. Materials used in definitive physical models or restorations within CAD-CAM technology can include ceramics, polymers, and metals (5,6). The purpose of this report is to provide a detailed account of the construction of auricular prostheses that utilize a 3D digital model to repair damaged areas.

Case Presentation

History

A 65-year-old male patient was referred to the Department of Prosthodontics at Tehran Dental Branch, Islamic Azad University, with a complaint of a missing right ear due to a history of an accident. On examination, a small remnant of the ear was present, along with a normal ear on the left side with normal hearing. Informed consent was obtained from the patient to use the photos for publication in the Journal of Basic Research in Medical Science (Figure1).

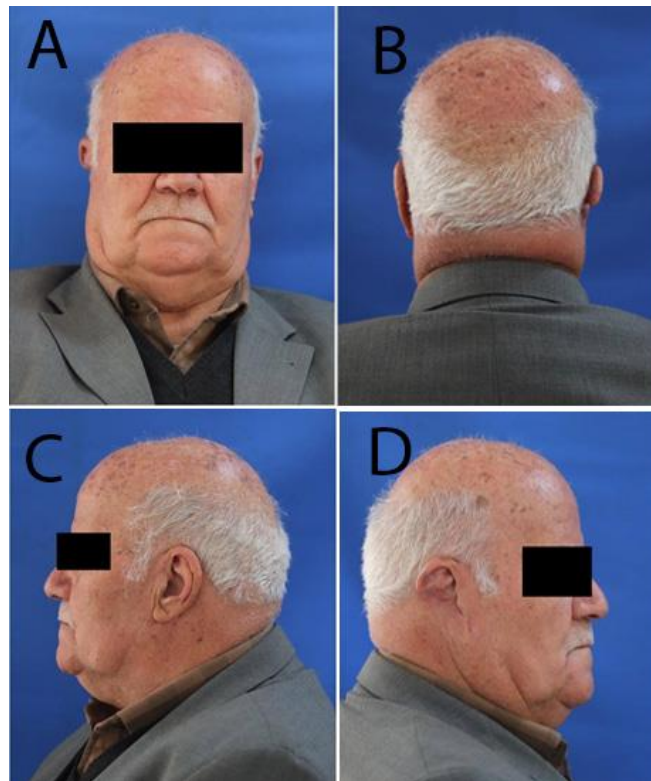

Figure 1. Clinical case presentation. A 65-year-old male patient presenting with the absence of the right ear, attributed to a history of trauma. **A)** Frontal view, **B)** Posterior View, **C and D)** Lateral View.

Treatment plan

The treatment plan was divided into four steps: impression, formation of pattern, flasking and curing, and eventually, the processing of the prosthesis material with internal and external staining.

Impression

To create an impression, the patient's head was positioned as horizontally as possible. The external auditory meatus

was blocked with a cotton pellet, and petroleum jelly was applied to the hair surrounding the area. Impressions of the auricular defect and the normal ear were made using irreversible hydrocolloid (Dentsply Sirona, USA). The surrounding areas of the ears were boxed and restricted by a suitable number of wax strips. After the alginate had set, the impressions were removed, boxed, and poured in type 3 gypsum material (Dentsply Sirona, USA) (Figure 2).

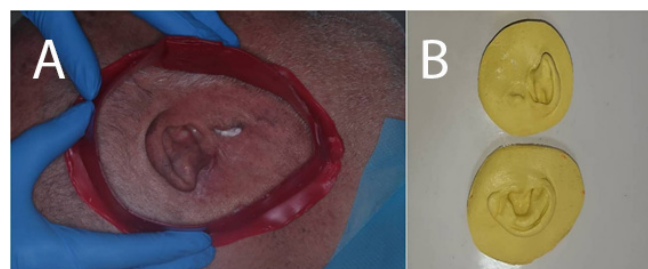


Figure 2. Creation of impression for an ear prosthesis. **A)** Restricted areas of the ears with wax strips, **B)** Casts were poured with gypsum

Pattern formation

During the initial step of pattern formation, the decision was made to employ an indirect scanner (Epson 1500W printer, USA) to scan the casts. Subsequently, a mirror image of the normal ear was generated, and the data was exported in Standard Tessellation Language (STL) format (Figure 3). The ASIGA MAX 3D printer from Italy was utilized to produce a printed resin pattern by mirroring the scanned cast images of both the normal and damaged ears.

In the process of creating auricular prostheses through a conventional mold and investment approach, a putty index

was derived from the digital resin model. Subsequently, wax was poured into the index, resulting in the production of a trial wax prosthesis that was then fitted to the patient. This fitting was meticulously evaluated for proper adaptation to the tissue, correct horizontal alignment with the opposite ear, and integrity during jaw movement.

To seamlessly blend the silicone edges with the natural skin, the edges were meticulously thinned as much as possible (Figure 3). This comprehensive method ensures the precise and effective fabrication of auricular prostheses, combining cutting-edge technology with traditional molding techniques.

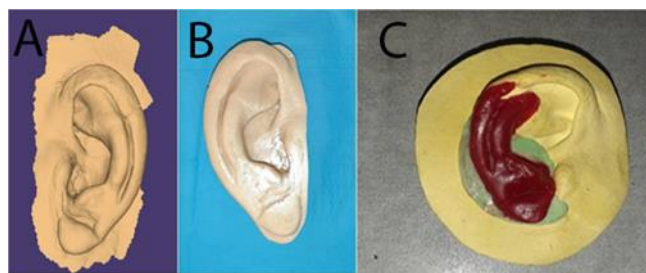


Figure 2. Pattern formation for an ear prosthesis. A) Scan of a normal ear, B) Printed resin pattern, C) Wax prosthesis attached to the cast.

Investment and fabrication of mold

The wax prosthesis was attached to the cast, and an ejector-type (three-piece) flask (OT FLASK-FLASK, A5705, Italy) was used to facilitate the removal of the prosthesis after processing with silicone. The wax pattern and cast were placed in the bottom half of the flask. A mix of plaster was poured into the bottom half of the flask, and cast separating medium was applied to the plaster. The middle section of the flask was added, and stone was poured in to cover the entire wax pattern undercuts. The land area of the wax

pattern and cast should be flush with the drag of the flask to prevent possible breakage of the two halves of the flask. After applying a separating medium, the helix undercut was poured with hard dental stone. Eventually, the cope of the flask was set approximately 3-6 mm away from the occlusal surface of the wax pattern.

Coloring technique

In the flasking and curing step, color matching of the silicone was an essential aspect. Color selection was applied in two

ways: intrinsic and extrinsic painting. Intrinsic colorants were added to uncolored silicone, prepared with liquid catalyst, based on skin tone. Additional colorants were mixed in small amounts of the base shade to create a variety of intrinsic staining colorants. The mold was filled with the modified base-shaded silicone, placed in a flask, and cured using a dry heat oven with a prescribed temperature. After the polymerization cycle was complete, the mold was allowed to cool to room temperature before removing the prosthesis.

External staining

External staining was applied to the surface of the prosthesis with a paintbrush to simulate the skin of the opposite ear,

including freckles, moles, blood vessels, and even sunburn areas. The silicones and materials used in extrinsic and intrinsic painting were from the Cosmosil brand (Japan).

Delivery

Retention was provided by a hollow extension into the helix zone, and skin adhesive was used for additional retention and sealing of the margins. The patient was instructed on how to use skin adhesive and assemble the prosthesis, as well as given necessary instructions on how to care for the prosthesis and keep it clean. To date, first and second follow-ups have been performed, and the patient is satisfied with the prosthesis (Figure 4).

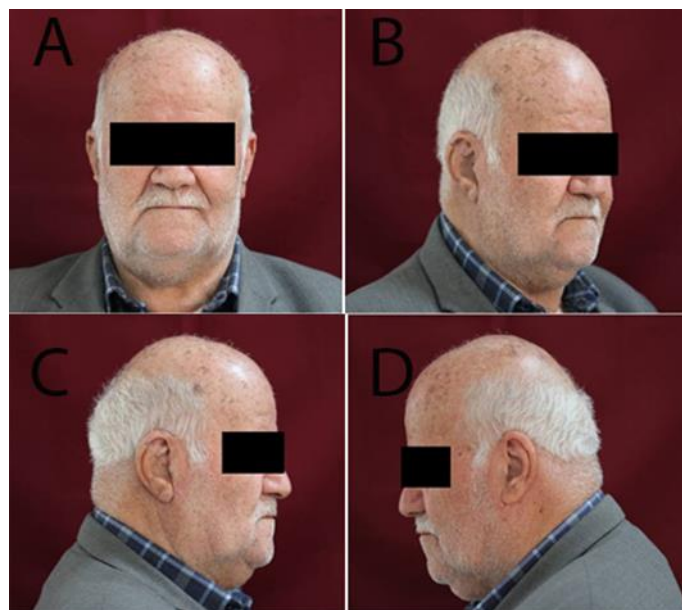


Figure 4. The 65-year-old male patient with the delivered right ear prosthesis, secured with a hollow extension and skin adhesive. Satisfactory outcomes were confirmed in first and second follow-ups. A) Prosthesis in frontal position view, B) Prosthesis in position $\frac{3}{4}$ view, C) Right ear prosthesis in lateral position view compared to D) the left normal ear.

Discussion

CAD/CAM technology has found diverse applications in the fabrication of auricular

prostheses (7). Recent advancements in the field of maxillofacial prosthetics, such as 3D rapid prototyping, have allowed

clinicians to enhance patient comfort and satisfaction. In this research, we aimed to achieve improved compatibility and aesthetics between damaged and normal ears through the use of digital technology (8).

Various techniques have been employed for creating digital impressions in maxillofacial prosthetics, including laser optical scanning, 3D photography, and spectrophotogrammetry (5). However, the necessary equipment for such techniques is often unavailable. Considering the available facilities, we chose to obtain a resin model derived from the mirror image of a normal ear cast to the damaged ear cast. This approach allowed for increased accommodation and aesthetics and, importantly, saved time, leading to a faster completion of the wax try-in process and readiness for flasking and processing.

Clinical reports have been published highlighting the use of CAD/CAM and rapid prototyping (RP) technology for fabricating auricular prostheses, emphasizing the speed and precision benefits of digital techniques. These advancements aid clinicians in providing the best possible treatment for patients (8). The materials used for auricular prostheses are typically based on acrylic and silicone. Silicone elastomeric materials offer advantages such as better stability and good marginal adaptation. However, a notable disadvantage of silicone materials is their susceptibility to degradation and ingredient changes when exposed to high temperatures, UV light, sunlight, and moisture over time, necessitating the replacement of the

prosthesis (9,10). In the journey of improving auricular prostheses, our use of digital technology has been a significant step. It promises a better future for those seeking to restore their ear's appearance and function, blending art and science for a promising future.

Conclusion

In our exploration of auricular prosthesis advancements, we have embraced digital technology. By crafting a digital resin model, we have achieved enhanced adaptability and aesthetics while streamlining the production process. This innovative approach holds great promise for individuals seeking a seamless and time-efficient restoration of their ear aesthetics.

Acknowledgements

The authors would like to express their gratitude to Dr. Farzad Yegane and the School of Dentistry at Azad University of Medical Sciences, Tehran, for their valuable contributions to this process.

Financial support

This Research project has been financially supported by School of Dentistry, Azad University of Medical Sciences, Tehran, Iran.

Conflict of Interests

The authors declare that there are no conflicts of interest.

Authors' Contributions

Mazaheri Azita: Conceived and designed the study, contributed to data acquisition and interpretation, drafted the manuscript, and critically revised the manuscript.

Zarbaksh Arash: Contributed to the study's conception, interpretation of data, drafted the manuscript, and critically revised it.

Karimi, Hamed: Contributed to the study's conception and design, acquisition and interpretation of data, drafted the manuscript, and critically revised it.

Rastin Verishe: Contributed to the study's design, acquisition, and interpretation of data, and participated in drafting and critically revising the manuscript.

All authors have given their final approval and agree to be held accountable for all aspects of the work.

References

1. Swaminathan AA, Prasad A. 2016. Fabrication of a silicone auricular prosthesis—a case report. *Journal of Health and Allied Sciences NU*. 6(01):091-097. doi: 10.1055/s-0040-1708627
2. Butler DF, Gion GG, Rapini RP. 2000. Silicone auricular prosthesis. *Journal of the American Academy of Dermatology*. 43(4):687-690. doi:10.1067/mjd.2000.107503
3. de Villaumbrosia PG, Martínez-Rus F, García-Orejas A, Salido MP, Pradíes G. 2016. In vitro comparison of the accuracy (trueness and precision) of six extraoral dental scanners with different scanning technologies. *The Journal of prosthetic dentistry*. 116(4):543-550. doi:10.1016/j.prosdent.2016.01.025
4. Lee J-J, Jeong I-D, Park J-Y, Jeon J-H, Kim J-H, Kim W-C. 2017. Accuracy of single-abutment digital cast obtained using intraoral and cast scanners. *The Journal of prosthetic dentistry*. 117(2):253-259. doi:10.1016/j.prosdent.2016.07.021
5. Liacouras P, Garnes J, Roman N, Petrich A, Grant GT. 2011. Designing and manufacturing an auricular prosthesis using computed tomography, 3-dimensional photographic imaging, and additive manufacturing: A clinical report. *The Journal of prosthetic dentistry*. 105(2):78-82. doi:10.1016/S0022-3913(11)60002-4
6. Turgut G, Sacak B, Kran K, Bas L. 2009. Use of rapid prototyping in prosthetic auricular restoration. *Journal of Craniofacial Surgery*. 20(2):321-325. Doi:10.1097/SCS.0b013e3181992266
7. Yadav S, Narayan AI, Choudhry A, Balakrishnan D. 2017. Cad/cam-assisted auricular prosthesis fabrication for a quick, precise, and more retentive outcome: A clinical report. *Journal of Prosthodontics*. 26(7):616-621.
8. Ciocca L, Scotti R. 2004. Cad-cam generated ear cast by means of a laser scanner and rapid prototyping machine. *The Journal of prosthetic dentistry*. 92(6):591-595. doi:10.1016/j.prosdent.2004.08.021
9. Kubon TM, Anderson JD. 2003. An implant-retained auricular impression technique to minimize soft tissue distortion. *The Journal of prosthetic dentistry*. 89(1):97-101. doi:10.1067/mpr.2003.16
10. Padmanabhan T, Mohamed K, Parameswari D, Nitin SK. 2012. Prosthetic rehabilitation of an orbital and facial defect: A clinical report. *Journal of Prosthodontics: Implant, Esthetic and Reconstructive Dentistry*. 21(3):200-204. doi:10.1111/j.1532-849X.2011.00817.x.