

## Aluminum phosphide poisoning, an unusual presentation

Alireza Ghodsi<sup>1</sup>, Bita Dadpour<sup>2</sup>, Zahra Shokri Toroghi<sup>3\*</sup>

1. Student Research Committee, Faculty of Medicine, Mashhad University of Medical Sciences, Mashhad, Iran
2. Medical Toxicology Research Center, Faculty of Medicine, Mashhad University of Medical Sciences, Mashhad, Iran
3. Clinical Research Development Unit, Imam Reza Hospital, Mashhad University of Medical Sciences, Mashhad, Iran

**\*Corresponding author:** Tel: +98 9155169068 Fax:-

Address: Faculty of medicine, Mashhad University of Medical Sciences, Azadi Sq., Mashhad, Iran

E-mail: zahra.shokri.t@gmail.com

Received; 23/07/2020 Revised; 16/08/2020 Accepted; 27/08/2020

### Abstract

Aluminum phosphide (ALP) is a very toxic compound commercially accessible as "rice tablet" in some markets in Iran. Although this toxin is used as a pesticide to protect grains from pests, it may be used for committing suicide. The poisoned patient experiences gastrointestinal problems as the first clinical manifestations in case of oral use, then develops acid-base disturbance, shock, and death in many cases. Intoxication with ALP can also affect the patient's hemodynamic status and cause electrocardiograph alterations, dysrhythmias, and even myocardial necrosis. In the current study, we introduce a young man who consumed an ALP tablet in a suicidal attempt and developed myocardial infarction even before metabolic acidosis and hypotension.

**Keywords:** Aluminum phosphide, Myocardial infarction, Phosphine, Poisoning

### Introduction

Aluminum phosphide (ALP), known as "rice tablet" or wheat pill, is a rodenticide, insecticide, and pesticide which is especially used in rural areas to protect stored grains (1). However, this material is commercially available in closed metal containers, and it is sold even in urban areas, which is illegal. In case of moisture exposure, a toxic gas is released from these tablets known as phosphine (2). Direct inhalation of these tablets or even exposure to the released gas can cause intoxication. The chance of mortality of poisoning with ALP is 30 to 100 percent, based on the patient's condition (3). The use of this toxin is an issue in several Asian countries including India, Sri Lanka,

Oman, and Iran. Poisoned patients usually develop hypotension, acidosis, and shock and may eventually die (1). Here, we present a case of intoxication with ALP who developed myocardial infarction even before developing metabolic acidosis.

### Case presentation

A 22-year-old Caucasian man presented with nausea and vomiting in the emergency room (ER) of the clinical toxicology department of Imam Reza Hospital (Mashhad, Iran). He declared that he had intentionally ingested one ALP tablet about half an hour before arrival at the ER. The patient had no gastrointestinal (GI) symptoms, such as

**Copyright © 2020 Journal of Basic Research in Medical Science.** This is an open access article distributed under the terms of the Creative Commons Attribution 4.0 International License (<https://creativecommons.org/licenses/by-nc/4.0/>), which permits copy and redistribute the material, in any medium or format, provided that the original work is properly cited.

hematemesis and epigastric pain, and did not complain of dyspnea or chest pain.

He was awake and oriented and had a pulse rate of 88 per minute, respiratory rate of 17 per minute, the temperature of 37 degrees Celsius, and systolic/diastolic blood pressure of 110/70 mmHg. The patient received gastric lavage by sodium bicarbonate and was transferred to the intensive care unit. The laboratory examination showed a white blood cell count of 9100 per microliter, hemoglobin of 19.3 g/dL, and a platelet count of 187 per microliter. In the venous blood gas assessment, the patient had a pH of 7.49, PCO<sub>2</sub> of 28.6, and HCO<sub>3</sub> of 23.1. Table 1 details the laboratory findings of the patient on different days of admission. An

electrocardiography (ECG) assessment was conducted which showed ST segment elevation (Figure 1). The patient's troponin level was also reported to be high. Cardiology consultation confirmed the extensive myocardial infarction (MI). For further assessment, the patient underwent echocardiography that showed an ejection fraction of 15% to 20%. Unfortunately, the patient status deteriorated despite all conservative treatments, such as magnesium sulfate, sodium bicarbonate, calcium gluconate, N-acetyl-cysteine (NAC), vitamins C and E, and hydrocortisone. The patient unfortunately deceased on the third day of admission.

**Table 1.** Laboratory assessment of the patient on different days of hospitalization.

Laboratory finding	Day 1	Day 1	Day 2	Day 2	Day 3	Day 3
	First lab	Second lab	First lab	Second lab	First lab	Second lab
WBC	9.1	15.5	3.3	10.7	-	-
Lymph %	40.5	9.5	23.5	80.5	-	-
Neut %	54.0	81.4	62.4	14.3	-	-
RBC	5.86	5.36	2.75	6.07	-	-
Hb	19.3	17.1	8.1	19.7	-	-
Hct	51.4	47.4	26.3	56.6	-	-
Plt	187	191	101	164	-	-
BS	-	100	-	113	-	-
Urea	-	17	-	55	-	-
Cr	-	0.9	-	1.7	-	-
AST	-	13	-	270	-	-
ALT	-	6	-	63	-	-
ALP	-	141	-	144	-	-
Bili (T, D)	-	(4.5, 0.4)	-	(7.7, 0.7)	-	-
CPK	-	156	-	-	-	-
CRP	-	1.8	-	-	-	-
Sodium	-	142	-	141	-	-
Potassium	-	3.6	-	4	-	-
PT	45	-	-	32	-	-
PTT	180	-	-	>180	-	-
INR	5.02	-	-	3.24	-	-
pH	7.49	7.30	7.29	-	7.33	7.18
Pao <sub>2</sub>	35.2	29.5	94.7	-	22.4	31.1
PCO <sub>2</sub>	28.6	48.8	27.2	-	43.5	55.1
HCO <sub>3</sub>	23.1	24.3	13.2	-	23.3	20
TPI	4.2	-	6667.3	-	-	-

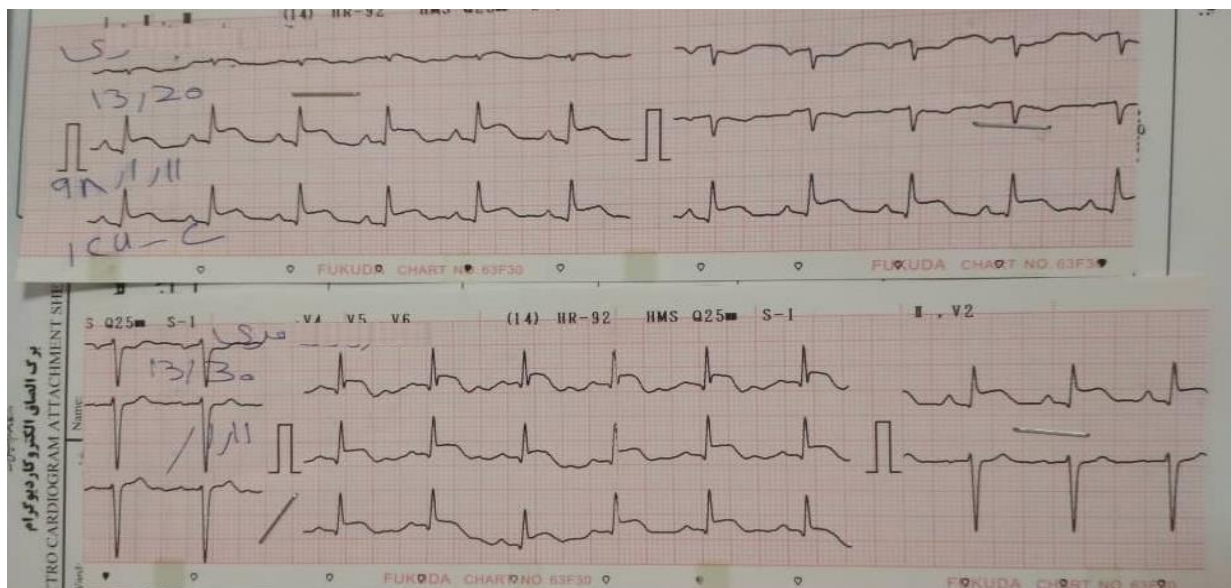


Figure 1. Electrocardiography of the patient.

## Discussion

Metal phosphides, such as aluminum phosphide, are very potent and cheap fumigants used to kill pests and rodents. These features have made aluminum phosphide a very popular option in developing countries including Iran. It is reported that intoxication with ALP causes around 300,000 deaths every year in all parts of the world (4). In Iran, it is associated with 18.6% to 24% mortality, and the highest rate of intoxication is reported from the northern part of Iran, especially the rural areas (5). Hosseinian et al. found that more than 90% of these cases have been intentional (6). Furthermore, Hassanian-Moghaddam et al. reported that ALP is the most common agent used for committing suicide in Tehran, especially in people under 30 years old (7). ALP tablets release the lethal gas of phosphine when exposed to water; poisoning can thus occur due to inhalation of this gas. However, in suicidal cases, patients are usually orally exposed to ALP and present with GI symptoms including nausea, vomiting, and epigastric pain. Along with these symptoms, patients may have dyspnea, retrosternal pain, anxiety, irritability, and

garlic smelling breath. These symptoms usually manifest within the first 10 to 15 minutes. Other GI symptoms are hematemesis and even dysphagia in some cases (8).

The ALP-poisoned patient may eventually develop signs of central nervous system disorders that may continue in the presence of shock and lead to a coma. Electrolyte abnormalities may also occur including hypernatremia, hyponatremia, hypokalemia, and hyperkalemia, which are associated with a poorer prognosis, based on the study of Mirakbari et al. (9). Metabolic acidosis or mixed metabolic acidosis and respiratory alkalosis are other complications which deteriorate the patients' status (9).

ECG abnormalities such as ST changes, inverted T wave, sinus tachycardia, AV block, and complete heart block may be observed in these cases, so cardiac monitoring and repeated ECG are required. These changes can be life-threatening in about half of the patients. The patients may have cardiac arrhythmia, toxic myocarditis, hypotension, and eventually shock. However, myocardial infarction (MI) is rare in these patients and usually occurs after acidosis

(10). In a rare condition, we found a case of MI without an evident preceding acidosis.

### Conclusion

ALP suicidal intoxication is a frequent issue in some Asian countries including Iran. The intentional use is often oral and followed by GI symptoms within the first few minutes. With a high rate of mortality, the patients may then develop acidosis, electrolyte abnormalities, shock, and eventually death. Cardiac manifestations may be observed in these patients. However, MI is a rare condition and usually occurs after developing

acidosis and hypotension. As reported in this case report, in rare situations, the patient may experience MI before developing acidosis. Physicians should be aware of some rare presentations of this lethal poisoning.

### Acknowledgments

We would like to thank all who helped us in this research work.

### Conflicts of interest

The authors declare that they have no conflict of interest.

### References

1. Faridaalae G, Rahmani SH, Ahmadi S, Mahboubi A. An interesting case of aluminum phosphide poisoning. *J Emerg Pract Trauma*. 2016;2(1):29-30. doi: 10.15171/jept.2015.07.
2. Kumar M, Reddy PS, Kiran J. Aluminum Phosphide Poisoning: A Rare Presentation. *Indian J Med Forensic Med Toxicol*. 2018;12(1):165-9. doi: 10.5958/0973-9130.2018.00033.6.
3. Hassanian-Moghaddam H, editor Phosphides and phosphine: Mechanisms for toxicity and range of the problem. *CLINICAL TOXICOLOGY*; 2014: INFORMA HEALTHCARE 52 VANDERBILT AVE, NEW YORK, NY 10017 USA.
4. Qureshi MA, Nadeem S, Ahmad T, Tariq F, Rehman H, Qasim AP. Aluminium Phosphide Poisoning: Clinical Profile and Outcome of Patients Admitted in a Tertiary Care Hospital. *Ann Punjab Med Coll*. 2018;12(3):191-4. doi: 10.29054/APMC.18.535
5. Alinejad S, Zamani N, Abdollahi M, Mehrpour O. A narrative review of acute adult poisoning in Iran. *Iran J Med Sci*. 2017;42(4):327.
6. Hosseinian A, Pakravan N, Rafiei A, Feyzbakhsh S. Aluminum phosphide poisoning known as rice tablet: A common toxicity in North Iran. *Indian J Med Sci*. 2011;65(4):143. doi: 10.4103/0019-5359.104777.
7. Hassanian-Moghaddam H, Pajoumand A. Two years epidemiological survey of aluminum phosphide poisoning in Tehran. *Iran J Toxicol*. 2007;1(1):35-9.
8. Hashemi-Domeneh B, Zamani N, Hassanian-Moghaddam H, Rahimi M, Shadnia S, Erfantalab P, et al. A review of aluminium phosphide poisoning and a flowchart to treat it. *Arch Indust Hyg Toxicol*. 2016;67(3):183-93. doi: 10.1515/aiht-2016-67-2784.
9. Mirakbari SM. A review of aluminium phosphide poisoning and a flowchart to treat it: recommendation for a revision. *Arh Hig Rada Toksikol*. 2017;68(1):74-. doi: 10.1515/aiht-2017-68-2934.
10. Eshraghi A, Rajaei N, Mood MB, Vakili V, Ramezani J. Changes of QT Dispersion in Patients Suffering from Aluminium Phosphide Poisoning (Rice Pill). *Maced J Med Sci*. 2019;7(14):2251. doi: 10.3889/oamjms.2019.564.