

Evaluation of the Camphor effects on histological parameters of skin in adult mice and the protective role of vitamin E

Mohammad Babaei^{1*}, Ali Kalantari Hesari², Salman Soltani³

1. Department of Clinical Sciences, Faculty of Veterinary Science, Bu-Ali Sina University, Hamedan, Iran
2. Department of Pathobiology, Faculty of Veterinary Science, Bu-Ali Sina University, Hamedan, Iran
3. Central Laboratory, University of Ilam, Ilam, Iran

*Corresponding author: Tel: +98 8134227350 Fax: +98 8134227475

Address: Department of Clinical Sciences, Faculty of Veterinary Science, Bu-Ali Sina University, Felestin Sq., Hamedan, IRAN

E-mail: mohammad.babaei@basu.ac.ir

Received: 7/11/2020 Revised: 11/01/2021 Accepted: 24/02/2021

Abstract

Introduction: Camphor is known to Asian nations for many centuries. The camphor can be used in traditional medicine as an aromatic substance, sexual thrills controller, for cosmetic uses such as the rose color of skin, stimulating blood circulation and respiratory system, mental stimuli, hair removal. In this study, we aimed to investigate the effects of camphor on the skin parameters and the protective role of vitamin E as a potent antioxidant in the treatment of complications of camphor.

Materials and Methods: In this study, 50 male mice (BALB/c) with 20-25 gr weight were used randomly in 5 groups. The control group received normal saline, and two of the groups as control-sham received olive oil alone and the combination of the vitamin E and olive oil. Finally, two experimental groups received camphor alone (30 mg/kg) with daily rubbing on the interscapular region and camphor with vitamin E (100 mg/kg) daily by gavage for 35 days. At the end of the period, the skin samples were taken, and after tissue processing and preparing sections, histological parameters were evaluated.

Results: The results showed a significant reduction in the number of hair follicles, changes in dermal thickness, and a maximum depth of follicles in the group received the camphor. While the vitamin E was slightly able to reduce the effects of camphor ($P < 0.05$).

Conclusion: It can be concluded that camphor causes a decrease in hair follicles, and vitamin E as an antioxidant can improve the adverse effects of camphor on skin quality.

Keywords: Camphor, Vitamin E, Skin, Hair, Mice

Introduction

The camphor is a waxy, white, or clear, and solid substance with the formula $C_{10}H_{16}O$, which has a very strong odor. Camphor is the gum of a tree called *Camphor laurel*, but nowadays, its industrial type has been produced and has been used widely in medicine, health, and industry (1- 3).

Camphor has various uses among countries, especially Asian countries, and has been known in east Asian countries for centuries. For example, it is used in herbal medicine as a disinfectant and anti-cold agent (4, 5). Also, in herbal medicine, the camphor can be used as an aromatic substance for cosmetic purposes such as reddening of the skin, stimulating blood flow and respiratory

Copyright © 2021 Journal of Basic Research in Medical Science. This is an open access article distributed under the terms of the Creative Commons Attribution 4.0 International License (<https://creativecommons.org/licenses/by-nc/4.0/>), which permits copy and redistribute the material, in any medium or format, provided that the original work is properly cited.

system, psychological stimulants, modulating sexual instincts, preventing pregnancy, and abortion. As well as, in herbal medicine, camphor is utilized to remove excess hair (depilatory substance) (6- 9). Industrial type of the camphor produces from turpentine oil and are available in the form of the ointments, lotions, and gels to prevent insect bites, antimicrobials, to embalm corpses, fireworks, UV filter oil, local analgesics, anti-itch, skin cooling and as a type of sunscreen (1- 3). It is also used for retrofitting plastic to sunlight, in pesticides, polishes, health and care products for bathrooms, cosmetics, and in some chewing gums and cigarettes (4, 5). Regarding the effects of camphor on the organs of the body, there is strong evidence that the vast majority express the harmful properties of this substance on the body. Ways of entry of this substance into the body are through food, skin, eye contact, and respiration. The camphor can be absorbed by way of the skin, gastrointestinal tract (5 to 90 minutes after ingestion), and respiratory tract. Including symptoms of intoxication with camphor can be noted blurred vision, nausea, vomiting, colitis, dizziness, delirium, myocardial contraction and difficulty breathing, seizures, and eventually death (6). So far, no comprehensive histological study has been performed on the effects of the camphor on skin and hair factors. Therefore, in the present study, the role of vitamin E as an effective substance in skin quality was evaluated along with the effects of the camphor on skin histological factors.

Materials and Methods

Animals

This experimental study was carried out on 50 healthy adults sexually mature male BALB/c mice (10 weeks of age, 25-30 g body weight). Animals were obtained from the Animal House of Faculty of Science, Tehran

University, Tehran, Iran. Animals housed in polycarbonate cages in an air-conditioned room (temperature: 25 ± 2 °C, relative humidity: $50 \pm 10\%$, and 12 h light/12 h dark photoperiod) free from any sources of chemical contamination with free access to standard diet and water throughout the experimental period. An adaptation period of two weeks was considered for animals before starting the experiment. The experimental protocols and procedures were carried out in accordance with international guidelines for care and use of laboratory animals and approved by the ethical committee of Tehran University.

Experimental Design

Following the adaptation period, mice were randomly divided into five groups (n=10); one control group, two control-sham groups, and two experimental groups. In the control group, animals received normal saline with volume of 0.3 ml in the form of rubbing. One of the control-shame groups received 0.3 ml of the olive oil alone in the form of rubbing, and another control-shame group received vitamin E (100 mg/kg daily by gavage) (10) with olive oil (0.3 ml in the form of rubbing). Finally, one of the experimental groups received camphor alone dissolved in olive oil (30 mg/kg) by rubbing (11), and the second experimental group received camphor dissolved in olive oil (30 mg/kg) by rubbing with vitamin E (100 mg/kg daily by gavage). According to the references and since the most suitable and least harmful solvent for camphor is olive oil, 30 mg/kg of camphor was dissolved in olive oil and administered by rubbing (12). The interscapular region was used for rubbing in animals. All animal treatments were carried out daily for 35 days.

Histological Analysis

At the end of the experiment, animals were euthanized by cerebrosplinal displacement, and then the skin samples were collected

from the interscapular region and fixed in 10% formalin buffer solution for histological evaluation. Tissue samples were embedded in paraffin blocks and sliced into 5-6 μ m-thick sections. The slices were stained using hematoxylin-eosin for the general histological examination and Masson's trichrome method as dedicated staining to detect of collagen fibers. Histomorphometrically evaluations were carried out with a digital camera Dino-Lite lens and Dino-capture 2 software. The thickness of the whole skin, layers of epidermis, dermis, and hypodermis, maximum depth of the hair follicles, and number of the hair follicles and sebaceous glands (in a circle with a radius of 1500 micrometers) were measured (13). Image Pro-plus version 6 software was used for image analysis of histochemical sections.

Statistical Analysis

All data were represented as the mean \pm standard deviation. Data distribution was controlled by the K-S test, and since the

distribution of all data was normal, parametric tests were used to analyze them. The variables were analyzed by one-way analysis of variance followed by Tukey test for post hoc comparisons using Statistical Package for the Social Sciences, version 18.0, SPSS Inc, Chicago, Illinois, USA. The statistical significance level was set at $P < 0.05$.

Results

Histomorphometrically Assessment

The measurement of the thickness of the whole skin and layers of the epidermis and hypodermis in control, control-shame, and experimental groups revealed that no significant difference was observed between different groups with each other (Figures 1 and 2). The assessment of the thickness of the dermis layer in control, control-shame, and experimental groups showed that only the Olive oil + Vitamin E group had a significant difference in comparison with the control group ($P < 0.05$).

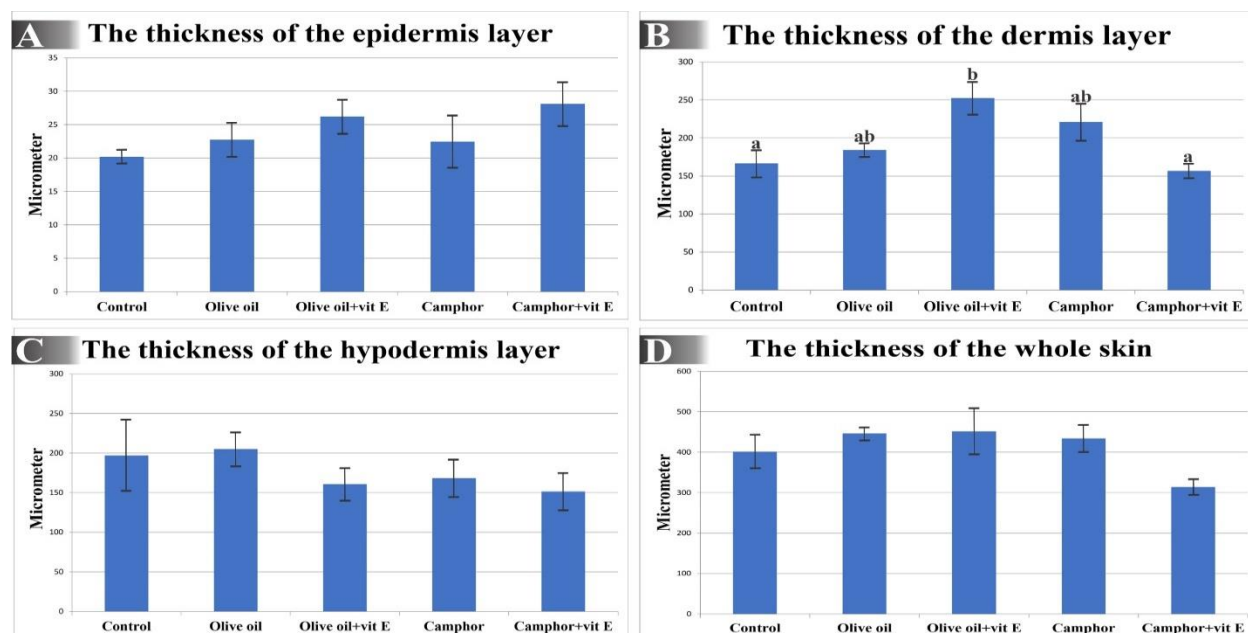


Figure 1. A: The mean thickness of the epidermis, B: dermis, C: hypodermis layers, and D: whole skin in control and experimental groups. Control animals received normal saline. All data were represented as the mean \pm standard deviation. The statistical significance level was set at $P < 0.05$. Different superscripts denote statistical difference at a $P < 0.05$.

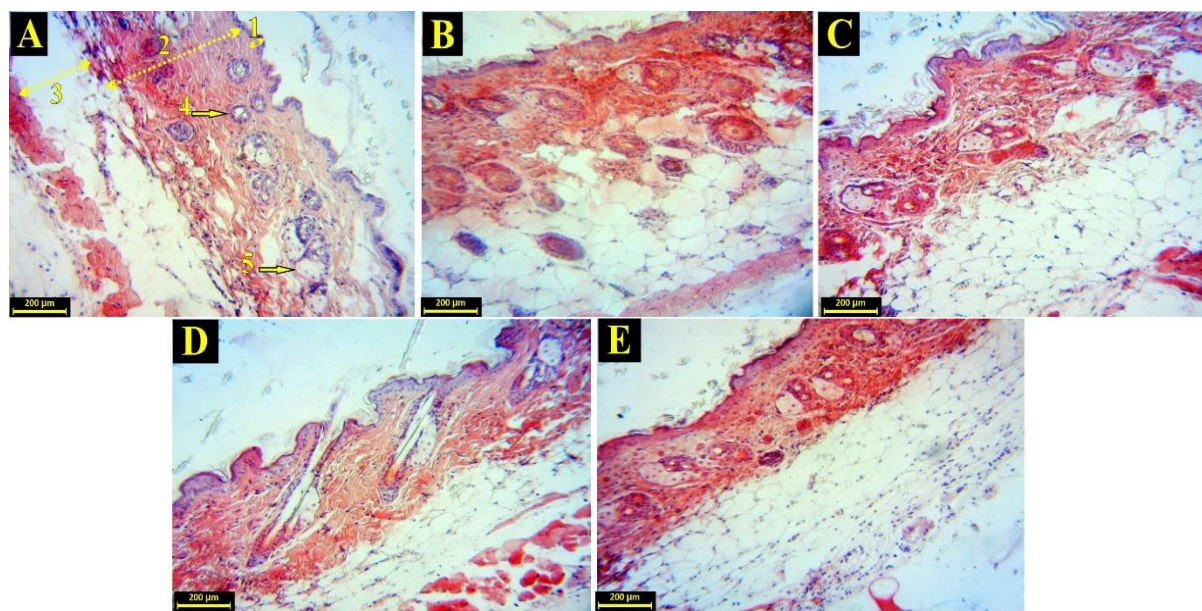


Figure 2. Histological sections of the skin (H & E staining). **A:** Control group, **B:** Olive oil group, **C:** Olive oil + Vitamin E group, **D:** Camphor group, **E:** Camphor + Vitamin E group. 1: Epidermis layer, 2: Dermis layer, 3: Hypodermis layer, 4: Hair follicle, 5: Sebaceous gland.

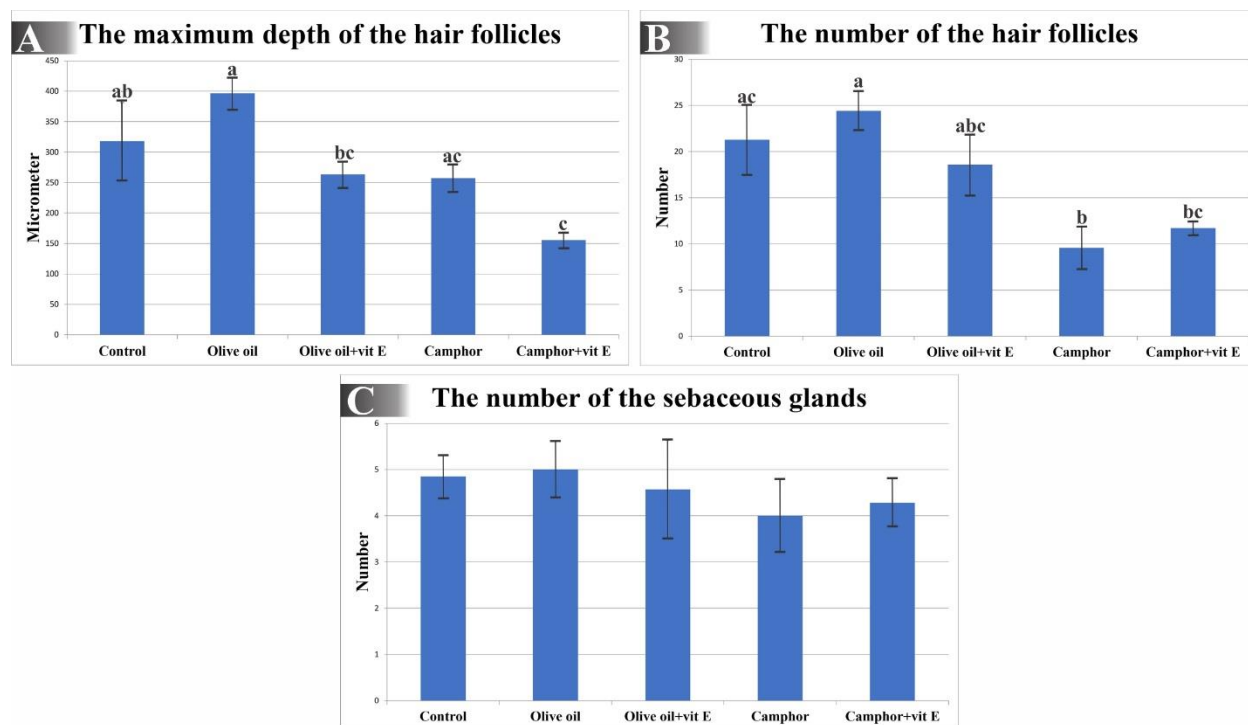


Figure 3. **A:** The mean of the maximum depth of the hair follicles, **B:** the number of the hair follicles, and **C:** the number of the sebaceous glands in control and experimental groups. **Control** animals received normal saline. All data were represented as the mean \pm standard deviation. The statistical significance level was set at $P < 0.05$. Different superscripts denote statistical difference at a $P < 0.05$.

Also, there was a statistically significant difference between Olive oil + vitamin E and

camphor + vitamin E groups ($P < 0.05$). There was no significant difference in comparison

with other groups. In comparison to other groups with each other, significant dissimilarities were not seen (Figures 1 and 2).

The mean evaluation of the maximum depth of the hair follicles in control, control-shame, and experimental groups indicated that the maximum depth of the hair follicles in the camphor + vitamin E group was significantly lower than the control group ($P < 0.05$). Also, the Olive oil group had a significant difference with Olive oil + vitamin E and camphor + vitamin E groups ($P < 0.05$). Other groups had any significant differences with each other (Figures 2 and 3).

The number of the hair follicles survey (in a circle with a radius of 1500 micrometers) in all groups exhibited that the camphor group was the only group with a significant difference from the control group ($P < 0.05$). Also, the Olive oil group had a significant difference compare with camphor and camphor + vitamin E groups ($P < 0.05$). The other groups did not differ significantly from each other (Figures 2 and 3). The sebaceous glands (in a circle with a radius of 1500 micrometers) number assessment demonstrated that there were any significant differences between groups with each other (Figures 2 and 3).

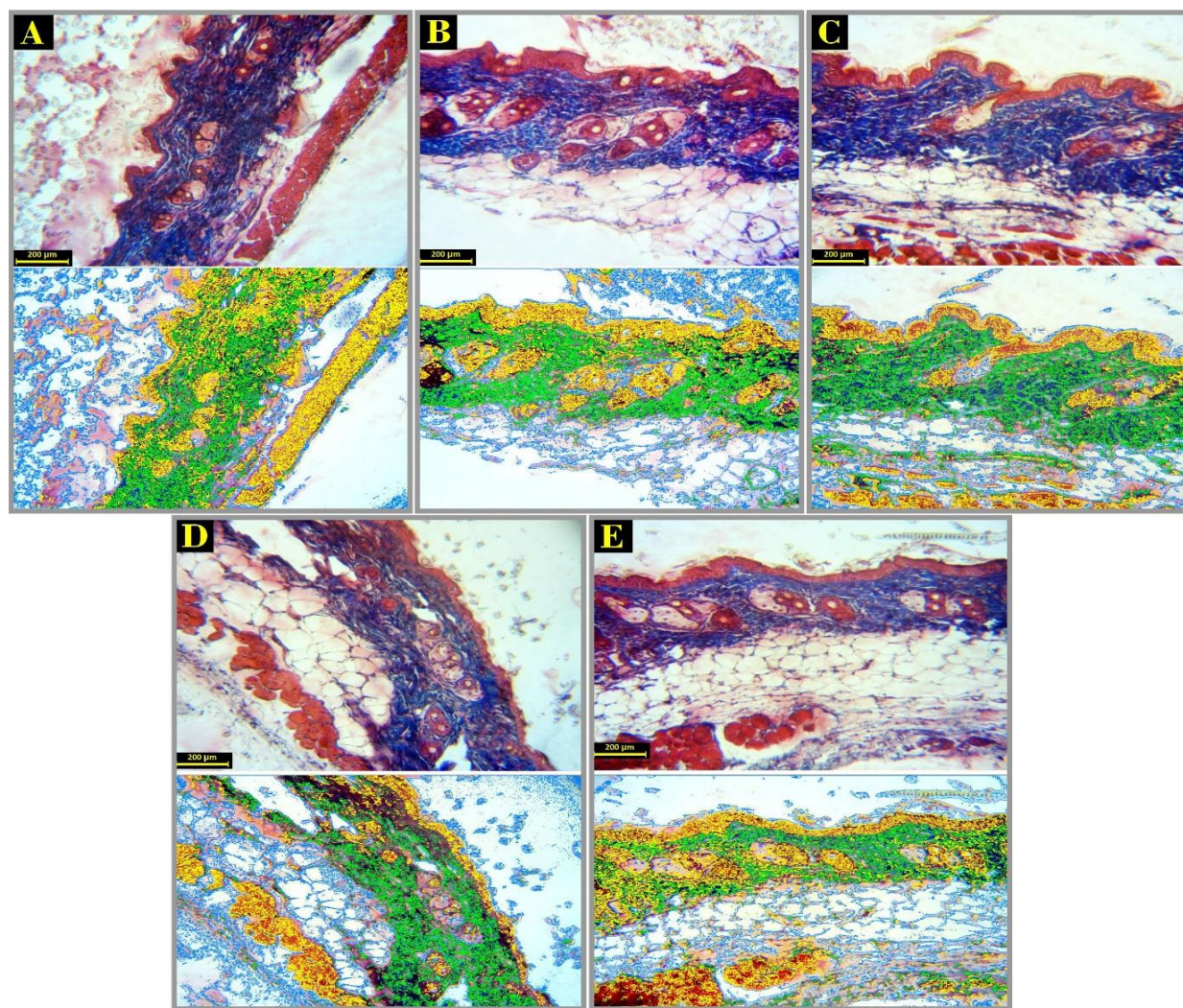


Figure 4. Histological sections of the skin (Masson's trichrome staining). **A:** Control group, **B:** Olive oil group, **C:** Olive oil + Vitamin E group, **D:** Camphor group, and **E:** Camphor + Vitamin E group.

Histochemical Evaluation

Investigation of the percentage of the collagen fibers in the dermis layer of the skin in control, control-shame, and experimental groups by Masson's trichrome method

indicated that only the Olive oil + vitamin E group had significant increase compared with other groups ($P < 0.05$). There were any significant differences between groups (Table 1, Figure 4).

Table 1. The percentage of collagen fibers in the dermis layer of skin which obtained from image analysis of Masson's trichrome staining.

Groups	The collagen fibers volume based on image analysis
Control	13.90 ± 1.86
Olive oil	14.36 ± 1.71
Olive oil + Vitamin E	25.34 ± 2.62
Camphor	11.43 ± 1.75
Camphor + Vitamin E	13.39 ± 1.61

Discussion

The skin, as the largest organ of the human body, plays an important role in maintaining the hemostasis of the body, which severe damage to this organ causes problems in survival. The skin includes epidermis and dermis layers that are located on the subcutaneous fat named hypodermis. The epidermis mainly contains keratinocyte layers where other cell types, including melanocytes and Langerhans cells, are scattered. The epidermis is separated from the dermis by a basement membrane. The dermis is composed of two layers, papillary and reticular, which include the extracellular matrix or the underlying material consisting of collagen, reticular fibers, elastin, and glycosaminoglycans (14).

Despite the small number of previous studies in this field, it is stated that camphor is capable of hydroxylation in positions 3, 5, 8, and 9 carbons. This hydroxylation in positions 5 and 8 (or 9) carbons will create hydroxy camphor, which followed by an oxidation reaction to produce ketones and carbon dioxide. This produced carbon dioxide-7 has the ability to conjugate with glucuronic acid (15). The glucuronic acid is used by the liver to detoxify certain compounds (16). This substance has three important functions in the body; 1.

Detoxification of toxic substances by conjugation and finally removing the toxic substance, 2. Hormones and other important substances transportation by combining with those substances and subsequently releasing substances in the target tissues, 3. Also, it is expressed that glucuronic acid participates as an intermediate substance in the synthesis of the ascorbic acid (17). It has been shown that the camphor inhibits glucuronic acid activity by binding to it (18).

The hyaluronic acid is a polymer composed of D-glucuronic acid and N-acetyl glucosamine units. The hyaluronic acid chains can contain 25,000 units, or more and the molecular weight of these chains varies between 5,000 and 20 million Daltons. Hyaluronic acid, also called hyaluronan, is the major and most important component of the extracellular matrix, is a glycosaminoglycan that absorbs water. There is a lot of hyaluronan in the damaged tissue being repaired or growing. The deficiency of hyaluronic acid is one of the main and basic causes of skin lesions. More than 50 percent of the total hyaluronic acid of the body is located in the skin and needed for stability and maintenance of the matrix and many cellular functions. The hyaluronic acid is high molecular weight and highly anionic polysaccharide with a smooth chain of the glycosaminoglycan consisting of variable

duplicate units of glucuronic acid and N-acetyl glucosamine (19). Nowadays, a unique enzyme capable of synthesizing hyaluronic acid has been identified, which is actually composed of two-way transferases that alternatively use the precursors of UDP-sugar, UDP-glucuronic acid, and N-UDP-acetylglucosamine (20). Based on the mentioned points and the role that glucuronic acid plays in detoxification and preservation of the main components of the dermis of the skin, change of the factors such as reduction of the number of the hair follicles, the thickness of the dermis layer, and maximum depth of the hair follicles in groups that were received camphor, can be attributed to mentioned points. Furthermore, vitamin E, as a powerful antioxidant, especially for the skin, was slightly able to prevent decreases of some parameters.

The present experiment was the first study of the effects of the camphor on histological parameters and subsequent skin quality. So, due to the poor research background and limited resources to justify the observed changes and need more research in this field, inevitably, the possible reasons for these changes were discussed in the present discussion.

It has been shown in studies in this field that rich compounds of glucuronic acid such as kombucha are useful for increasing lifespan, treating cancer, fighting acne, eliminating wrinkles, treating rheumatism, increasing the number of T-cells, treating asthma, increasing vitality, and restoring white hair color to their natural (21). Also, according to Cvetkovic and Markov, glucuronic acid is one of the most important therapeutic metabolites that contributes to the detoxification properties of many herbal medicines (22).

The glucosamines are the byproduct of the glucuronic acid. The glucosamines are a component of the glycosaminoglycans (including hyaluronic acid, keratan sulfate,

chondroitin sulfate, heparan sulfate, and heparin), which are important components of the extracellular matrix and one of the effective factors in the healing process (23, 24). Most of the glycosaminoglycans bind covalently to the protein nucleus to form proteoglycans. The hyaluronic acid is an exception that does not participate in the formation of proteoglycans (24). In wound formation, extracellular matrix compounds play key roles in stimulating cell proliferation and differentiation, guiding cell migration, and regulating cellular response (23, 25, 26). In addition, after studies by Gilbert et al, chondroitin sulfate hydrogel was identified as a substitute for extracellular matrix, reservoir of cytokines and growth factors and structure for fibroblast migration, and epithelial formation (27).

McPherson et al confirmed the important role of heparan sulfate (HS) in cell growth, development and angiogenesis. Also, they introduced heparan sulfate as an essential cofactor for binding of FGF receptor (28). There is a study that has proofed an increased level of hyaluronic acid in wound healing without scar in the fetus (29). Furthermore, based on the research by Foschi et al, hyaluronic acid causes a decline in the damage to granular tissue by digesting free radicals (30). The mentioned studies somehow justify the changes that have occurred in this experimental study and are consistent with it.

The transient receptor potential channels (TRPs) are a large group of ionic channels that control many physiological activities of the body, and there are different types of these channels (31). Cahusac, in 2009, has shown that the camphor could be involved in inactivating or reducing the activity of TRPs in the sinuses of hair follicles in rats and inactivates all channels (32). The results of this study are one of the most important and strong reasons for reducing the number of hair follicles due to camphor consumption,

which was completely consistent with the results of the present study.

Conclusion

Finally, it can be said that the consumption of camphor, based on a series of misconceptions, especially in Asian countries, has detrimental effects on the quality and beauty of the skin histological structure. Also, the camphor utilization reduces the number and stability of follicles and the thickness of the dermis layer of the skin. So that even a potent antioxidant such

as vitamin E could mildly prevent these changes. However, it seems that additional and molecular studies are needed in this field.

Acknowledgments

Authors gratefully acknowledge the help and financial support of Bu Ali Sina University, Hamedan, Iran (Grant No. 99-153) and Tehran university in this study.

Conflict of interest

The authors declare that they have no conflict of interest.

References

1. Anczewski W, Dodziuk H, Ejchart A. Manifestation of chiral recognition of camphor enantiomers by alpha-cyclodextrin in longitudinal and transverse relaxation rates of the corresponding 1:2 complexes and determination of the orientation of the guest inside the host capsule. *Chirality*. 2003;15(7):654-9. doi: 10.1002/chir.10277.
2. Lattanzi A, Iannece P, Vicinanza A, Scettri A. Renewable camphor-derived hydroperoxide: synthesis and use in the asymmetric epoxidation of allylic alcohols. *Chem Commun (Camb)*. 2003;(12):1440-1.
3. Yu SC, Bochet A, Le Bas G, Chéron M, Mahuteau J, Grossiord JL, et al. Effect of camphor/cyclodextrin complexation on the stability of O/W/O multiple emulsions. *Int J Pharm*. 2003;261(1-2):1-8. doi: 10.1016/s0378-5173(03)00261-8.
4. Chatterjee N, Alexander GJ. Anticonvulsant properties of spirohydantoin derivatives from optical isomers of camphor. *Neurochem Res*. 1986;11(12):1669-76. doi: 10.1007/BF00967745.
5. Liu C, Mishra A, Tan R, Tang C, Yang H, Shen Y. Repellent and insecticidal activities of essential oils from *Artemisia princeps* and *Cinnamomum camphora* and their effect on seed germination of wheat and broad bean. *Bioresour Technol*. 2006;97(15):1969-73. doi: 10.1016/j.biortech.2005.09.002.
6. Freyer AM. *Drugs in Pregnancy and Lactation 8th Edition: A Reference Guide to Fetal and Neonatal Risk*. *Obstet Med*. 2009;2(2):89. doi:10.1258/om.2009.090002.
7. Goel H, Singh S, Adhikari J, Rao A. Radiomodifying effect of camphor on the spermatogonia of mice. *Jpn J Exp Med*. 1985;55(6):219-23. doi: 10.1016/0165-1218(89)90151-1.
8. Liebelt EL, Shannon MW. Small doses, big problems: a selected review of highly toxic common medications. *Pediatr Emerg Care*. 1993;9(5):292-7. doi:10.1097/00006565-199310000-00008.
9. Buckley G. *Martindale: The extra pharmacopoeia (29th edition)*. *J R Coll Gen Pract*. 1989;39(327):440.
10. Ganesh E, Chowdhury A, Malarvani T, Ashok-varadhan N. Hepatoprotective effect of Vitamin-E & C in Albino rats. *Int J Adv Lif Sci*. 2012; 3:21-6.
11. Nikravesh MR, Jalali M. The effect of camphor on the male mice reproductive

- system. *Urol J*. 2004;1(4):268-72. doi: 10.22037/uj.v1i4.298.
12. Budavari S, O'Neil MJ, Smith A, Heckelman PE, Obenchain Jr JR, Gallipeau JA, D'Arecea MA. *The Merck index: An encyclopedia of chemicals, drugs, and biologicals*. Whitehouse Station, NJ: Merck & Co Inc. 1996. doi: 10.1002/ddr.21085.
 13. Ikawa A, Ishii Y, Suzuki K, Yasoshima A, Suzuki N, Nakayama H, Takahashi S, Doi K. Age-related changes in the dorsal skin histology in Mini and Wistar rats. *Histol Histopathol*. 2002;17(2):419-26. doi: 10.14670/HH-17.419.
 14. Pomahač B, Svensjö T, Yao F, Brown H, Eriksson E. Tissue engineering of skin. *Crit Rev Oral Biol Med*. 1998;9(3):333-44. doi: 10.1177/10454411980090030601.
 15. Köppel C, Tenczer J, Schirop T, Ibe K. Camphor poisoning. *Arch Toxicol*. 1982;51(1):101-6.
 16. Frank G. *Healthy beverage from the Far East, Its correct preparation and use*. Germany: Ennsthaler, Steyr. 1996.
 17. Oser BL, Hawk PB. *Hawk's physiological chemistry*. McGraw-hill; 1965.
 18. Rabl W, Katzgraber F, Steinlechner M. Camphor ingestion for abortion (case report). *Forensic Sci Int*. 1997;89(1-2):137-40. doi: 10.1016/S0379-0738(97)00099-6.
 19. Lee JY, Spicer AP. Hyaluronan: a multifunctional, megaDalton, stealth molecule. *Curr Opin Cell Biol*. 2000;12(5):581-586. doi: 10.1016/S0955-0674(00)00135-6.
 20. Weigel PH, Hascall VC, Tammi M. Hyaluronan synthases. *J Biol Chem*. 1997;272(22):13997-4000. doi: 10.1074/jbc.272.22.13997.
 21. Hauser SP. *Teepilz Kombucha nach Dr. med. Sklenar--eine biologische Krebstherapie*. Dokumentation Nr. 18 [Dr. Sklenar's Kombucha mushroom infusion--a biological cancer therapy. Documentation No. 18]. Schweiz Rundsch Med Prax. 1990;79(9):243-6. German.
 22. Cvetković DD, Markov SL. Cultivation of tea fungus on malt extract medium. *Acta Period Technol*. 2002; 33:117-24. doi: 10.2298/APT0233117C.
 23. Clark RA. Biology of dermal wound repair. *Dermatol Clin*. 1993;11(4):647-66. doi:10.1016/S0733-8635(18)30218-3.
 24. Couchman JR, Höök M. *Proteoglycans and wound repair. The molecular and cellular biology of wound repair*. Boston: Springer; 1988.437-70.
 25. Mac Neil S. What role does the extracellular matrix serve in skin grafting and wound healing? *Burns*. 1994;20: S67-S70. doi: 10.1016/0305-4179(94)90094-9.
 26. Midwood KS, Williams LV, Schwarzbauer JE. Tissue repair and the dynamics of the extracellular matrix. *Int J Biochem Cell Biol*. 2004;36(6):1031-7. doi: 10.1016/j.biocel.2003.12.003.
 27. Gilbert ME, Kirker KR, Gray SD, Ward PD, Szakacs JG, Prestwich GD, Orlandi RR. Chondroitin sulfate hydrogel and wound healing in rabbit maxillary sinus mucosa. *Laryngoscope*. 2004;114(8):1406-9. doi: 10.1097/00005537-200408000-00017.
 28. McPherson JM, Ledger PW, Ksander G, Sawamura SJ, Conti A, Kincaid S, et al. The influence of heparin on the wound healing response to collagen implants in vivo. *Collagen Rel Res*. 1988; 8(1):83-100. doi: 10.1016/S0174-173X(88)80037-2.
 29. McCallion R, Ferguson M. Fetal wound healing and the development of antiscarring therapies for adult wound healing. In: *The molecular and cellular biology of wound repair*. Boston: Springer; 1988.561-600.
 30. Foschi D, Castoldi L, Radaelli E, Abelli P, Calderini G, Rastrelli A, Mariscotti C, Marazzi M, Trabucchi E. Hyaluronic acid

- prevents oxygen free-radical damage to granulation tissue: a study in rats. *Int J Tissue React.* 1990;12(6):333-9.
31. Srivastava S, Kumar P, Singh V, Singh D. Seasonal variation in abiotic factors and toxicity of thymol against the snail *Lymnaea acuminata*. *J Biol.* 2013;3(1): B1-B7. doi: 10.1111/zph.12024.
32. Cahusac PM. Effects of transient receptor potential (TRP) channel agonists and antagonists on slowly adapting type II mechanoreceptors in the rat sinus hair follicle. *J Peripher Nerv.* 2009;14(4):300-9. doi: 10.1111/j.1529-8027.2009.00242.x.