

Nandrolone decanoate administration can increase apoptosis in spermatogenesis cell lines in male rats

Saeed Shokri¹, Tahmineh Mokhtari², Monireh Azizi³, Hojjat-allah Abbaszadeh⁴, Ardeshir Moayeri^{*3}

1. Department of Anatomy, Faculty of Medicine, Zanjan University of Medical Sciences, Zanjan, Iran
2. Department of Anatomy, Faculty of Medicine, Tehran University of Medical Sciences, Tehran, Iran
3. Department of Anatomy, Faculty of Medicine, Ilam University of Medical Sciences, Ilam, Iran
4. Cellular and Molecular Research Center, Faculty of Medicine, Shahid beheshti University of Medical Sciences, Tehran, Iran

* **Corresponding author:** Tel: +988432235713; fax: +9832227136

Address: Department of Anatomy, Faculty of Medicine, Ilam University of Medical Sciences, Ilam, Iran

E-mail: moayeri46@yahoo.com

Received 20/12/2014; revised 22/12/2014; accepted 28/12/2014

Abstract

Introduction: Anabolic – androgenic steroids (AAS) are used at high doses by athletes for improving athletic ability, muscle mass and physical appearance. Unfortunately, the abuse of these agents has been significantly increased. It has been established that exercise and high doses of AAS may influence the hypothalamic-pituitary-gonadal axis, which can in turn affect testicular apoptosis and male fertility. However, the effect of the combination of exercise and high doses of AAS on testicular apoptosis is not known. This study investigated combined effects of exercise and high doses of nandrolone decanoate (an AAS) on the sperm quality, male sex organs weight and spermatogenic apoptosis.

Materials and methods: For the study 30 rats were randomly divided into three different groups (10 animals in each group). Group A, control (Cont), without any injection; group B, (sham) rats received solvent of nandrolone decanoate (peanut oil) and in group C, nandrolone decanoate was injected intramuscularly at a dose of 10 mg/kg per week for eight weeks.

Results: Body weight changes were shown to be different significantly between control and experiment groups ($P < 0.0001$). Prostates and seminal vesicles weight were significantly different between control and experiment groups (respectively, $P < 0.05$ and $P < 0.001$). Related right and left testes weight was significantly decreased in the experiment group compared to the control group (respectively, $P < 0.01$ and $P < 0.05$). Sperm quality markers were significantly different between control and experiment groups ($P < 0.0001$). The number of normal germ cells in experiment group was decreased in compared with control group.

Conclusion: This study concluded that nandrolone decanoate could decrease infertility rate in male system.

Keywords: Nandrolone Decanoate, apoptosis, testis, rat

Introduction

Spermatogenesis is an elongated, complex and finely tuned process. During this process, the developing sperm cell is sensitive to endogenous or exogenous stresses. Exposure to reproductive cytotoxic agents may damage germ cells or somatic testicular cells at different

stages of differentiation, leading to a temporary or permanent impairment of fertility (1). DNA damage can lead to cell death directly or through apoptosis, to the induction of mutations, and to the inhibition of DNA production (2).

Anabolic-androgenic steroids (AAS) are synthetic compounds which are based on the structure of testosterone, and are used to treat various conditions such as reproductive system dysfunction, breast cancer and anemia. Three basic modifications are made to the structure of testosterone to enhance deliverability and potency and slow down rate of degradation. This modification, which is made to injectable AAS, slows down degradation but enhances their androgenic properties (2). AAS are taken by abusing athletes at supraphysiological doses; such doses are usually 10 to 100 fold the recommended therapeutic dose. Defining the exact adverse effects of AAS abuse is very hard due to the lack of clinical trials which mimics AAS abuse by athletes (3). In addition, almost all major tissues in the body have androgen receptors, and therefore AAS abuse affects almost all body systems (2). To the best of our knowledge, although many studies have investigated the effects of testosterone suppression on spermatogenesis through sperm output evaluation (4), there are no reports on the effects of AAS abuse upon structural changes of the testis or sperm chromatin integrity. Hence, this work was conducted to evaluate the effects of administration of nandrolone decanoate at supra-physiological doses on male reproductive system (5).

AAS have effects on a wide variety of body tissues. Their fundamental physiological action is thought binding to an intracellular protein (receptor) in the target tissue. This AAS-receptor complex then substitutes to binding sites on chromatin, promoting gene transcription and subsequent mRNA synthesis. The effects of steroids vary in different tissues according to the local environment, such as the types of enzyme (e.g. 5 alpha-reductase and aromatises) and receptor presence. However, the specific biological mechanisms responsible for changes in strength and body composition are not clearly known (6). Testosterone itself is

relatively ineffective when taken orally or injected in an aqueous solution because it is relatively rapidly breakdown by the liver before it can act on the target organ that, in the case of athletes, is skeletal muscle. Consequently, the chemical structure of testosterone has been modified to overcome this problem. Most commonly, AAS are taken orally or by intra-muscular injection .

More recently, gels and creams are being used by most athletes for the purpose of circumventing drug testing. Bodybuilders desire to have more lean mass and less fat. Weightlifters desire to lift the maximum amount of weight possible (2). Field athletes want to put the shot, or throw the hammer, discus or javelin farther than their competitors or holders of previous records. Swimmers and runners hope to be able to perform frequent, high intensity, long duration workouts without physical breakdown. Other AAS users simply want to 'look good' which too many people means being big and muscular (6).

The short-term health effects of AAS have increasingly been studied, and several authors have reviewed the physiological and health effects of these drugs. Although AAS use has been associated (mainly through case reports) with several adverse and even fatal effects, the incidence of serious effects reported has been extremely low .

Reactive oxygen species (ROS) are free radicals such as the hydroxyl radical (OH^\bullet) and the superoxide anion ($\text{O}_2^{\bullet -}$), or molecules such as hydrogen peroxide (H_2O_2). The production of ROS is a normal physiological event in different tissues, including the testis. However, the overproduction of ROS stimulates DNA fragmentation and can be risky to sperm function, associated with peroxidative damage to the mitochondria and plasma membrane. This study was undertaken in order to examine effects of supra physiological doses of nandrolone deaconate on the apoptotic changes in rat testes (2). Nandrolone deaconate probably

is able to raise infertility rates by destructive effects on sperm parameters and apoptotic change upon spermatogenesis cell lines in testes. On the other hand, as a whole, the present study was conducted to evaluate the effects of weekly injections of nandrolone deaconate for eight weeks on the sperm quality and sex organs weight in the rats' model in order to connect the near relation with athletes who abuse AAS.

Materials and methods

Chemicals: Nandrolone deaconate (25 mg/ml) was purchased from Iran Hormone Company (Tehran, Iran). In Situ Cell death detection kit, Converter-POD (anti-fluorescein antibody, Fab fragment from sheep and conjugated with horse-radish peroxidase-POD) and diaminobenzidine (DAB) substrate was purchased from BoehringerMannheim GmbH (Mannheim, Germany). Epoxy resin araldite CY212 was purchased from TAAB Laboratories (Berks, UK). Caspase-3 kit was purchased from Sigma (St Louis, MO, USA).

Animals: Animals were maintained according national guidelines and protocols, approved by the Institutional Animal Ethical Committee (IAEC no. 03/028/07). Healthy adult male albino rats of Wistar strain from in-house breeding colony weighing 150–200 g were randomly selected from the Laboratory Animal Center of Tehran University of Medical Sciences. The animals were housed in a specific pathogen-free environment and well-ventilated animal house. After 1-week accommodation, they were placed in clean metal cages under a 12-hr light: dark cycle with a room temperature of 22°C to 25°C. The rats were fed a standard laboratory diet (Pars dam factory, Tehran, Iran) and clean drinking water was available at libitum.

Treatment: The rats were randomly divided into three different groups of 10 animals each. Group A, control group (Cont), without any injection; group B, (sham) rats received the solvent of

nandrolone decanoate (peanut oil) as a vehicle; and in group C, nandrolone decanoate (N) was injected intramuscularly at a dose of 10 mg/kg per week for eight weeks.

Laboratory studies: The change in body weight for each group was defined as the difference between initial and final body weights. After weighing, animals were anaesthetized with a mixture of xylazine (35 mg / kg) and ketamine (45 mg / kg) intraperitoneally (24 hr after the final treatment) and testes were carefully dissected out, cleaned of adhering connective tissue and accurately weighed (7).

The organ to body weight ratio were then calculated. Both testes were quickly removed and weighed. The samples of testicular tissues were fixed in a buffered 10% formaldehyde solution and were then embedded in paraffin wax using standard techniques .

Sections (each section: 5 μ m) were cut and made ready for TUNEL [terminal deoxynucleotidyl transferase (TdT) enzymemediated dUTP nick end labeling] staining. Histopathological evaluation of spermatogenesis.

Evaluation of germ cell apoptosis: Germ cell apoptosis was evaluated by TUNEL according to the instructions in the TUNEL assay kit (Boehringer Mannheim GmbH). In brief, serial 5 μ m thick paraffin-embedded sections were deparaffinized and rehydrated in graded alcohol. The slides were microwave-pre treated in 10 mM citrate buffer (pH 6.0) for 10 min. and were incubated with blocking solution (3% H₂O₂ in methanol) for 10 min. After washing in phosphate-buffered saline (PBS), the specimens were incubated with TUNEL reaction mixture (terminal deoxynucleotidyl transferase and nucleotide mixtures in reaction buffer) at 37°C for 60 min. After washing, the slides were stained with Converter-POD (antifluorescein antibody, Fab fragment from sheep and conjugated with horse-

radish peroxidase-POD) at 37°C for 30 min .

DAB substrate was applied for colour development. Positive cells containing fragmented nuclear chromatin characteristic of apoptosis would display a brown nuclear stain. For each group, the number of stained cells was counted in 10 tubules in the areas without necrosis. For each group, the number of stained germ cells was counted (7).

Nandrolone decanoate injection period were selected according to the spermatogenesis period in rats. The period of spermatogenesis in rats was approximately 48–56 days; therefore, 8-week nandrolone decanoate injection (56 days) seemed to be a reasonable period for assaying of spermatogenesis (7).

Statistical analysis

Results were analyzed by the SPSS version16. All data were expressed as mean values and their standard errors (S.E.). The variables were analyzed by one-way analysis of variance (Anova) with nandrolone decanoate. When a significant administration effect was found, Tukey post hoc test was performed. The statistical significance level was set at $P < 0.05$.

Results

Body weight changes percentage were analyzed among three groups of control, sham and experiment. Significant differences were shown among the groups ($P < 0.0001$, figure 1).

Also, Prostates and seminal vesicles weight were evaluated in three groups of studying and there was a significant difference between control and experiment groups (respectively, $P < 0.05$ and $P < 0.001$, figure 1).

Related right and left testes weight was evaluated in three groups of studying. According to the figure 2, the right and left testes weight was significantly decreased in the experiment group compared to the control group (respectively, $P < 0.01$ and $P < 0.05$).

Sperm count, morphology, viability and motility were analyses in three groups of control, sham and experiment. According to the results in figure 3, the mean sperm count among the groups was also significantly different. The results showed that a significant difference between experiment and control groups ($P < 0.001$). Mean normal sperm percentage was significantly different between experiment and control groups ($P < 0.0001$, figure 3). Viability was also significantly different between the groups. There was also a significant differences between control and experiment groups ($P < 0.0001$, figure 3). Also, total motility (A+C+D) was significantly different among the groups under study ($P < 0.001$, figure 3) (7, 8).

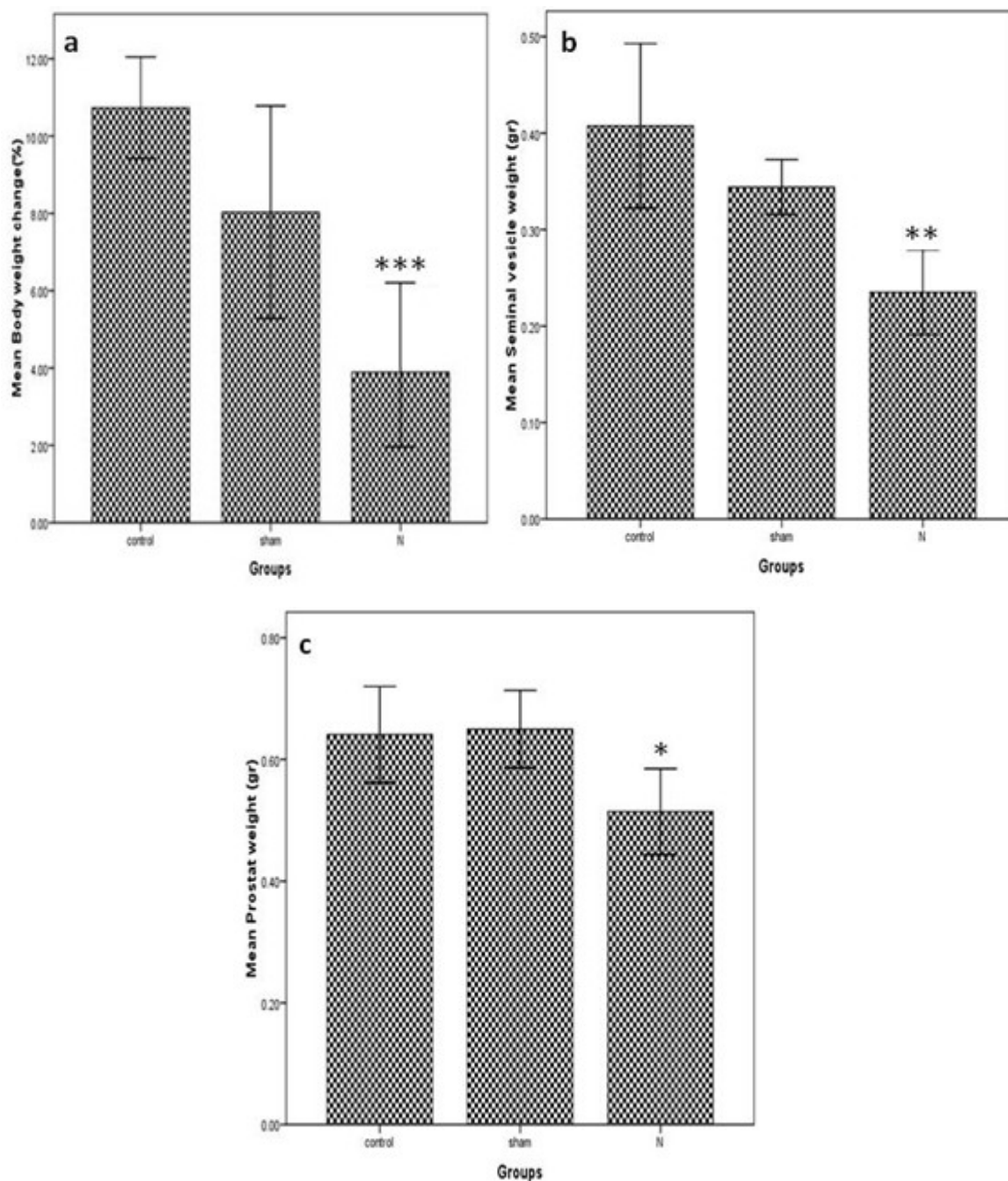


Figure1. Comparison of body weight change (as percentage) and reproductive organs weight among three groups of Control, sham and N (experiment). (a) Body weight changes. (b) Seminal vesicles weight. (c) Prostates weight. 10 rats were included in each group.

* $P < 0.05$: comparison between sham and control groups.

** $P < 0.001$: comparison between experiment and sham groups.

*** $P < 0.0001$: comparison between experiment and control groups.

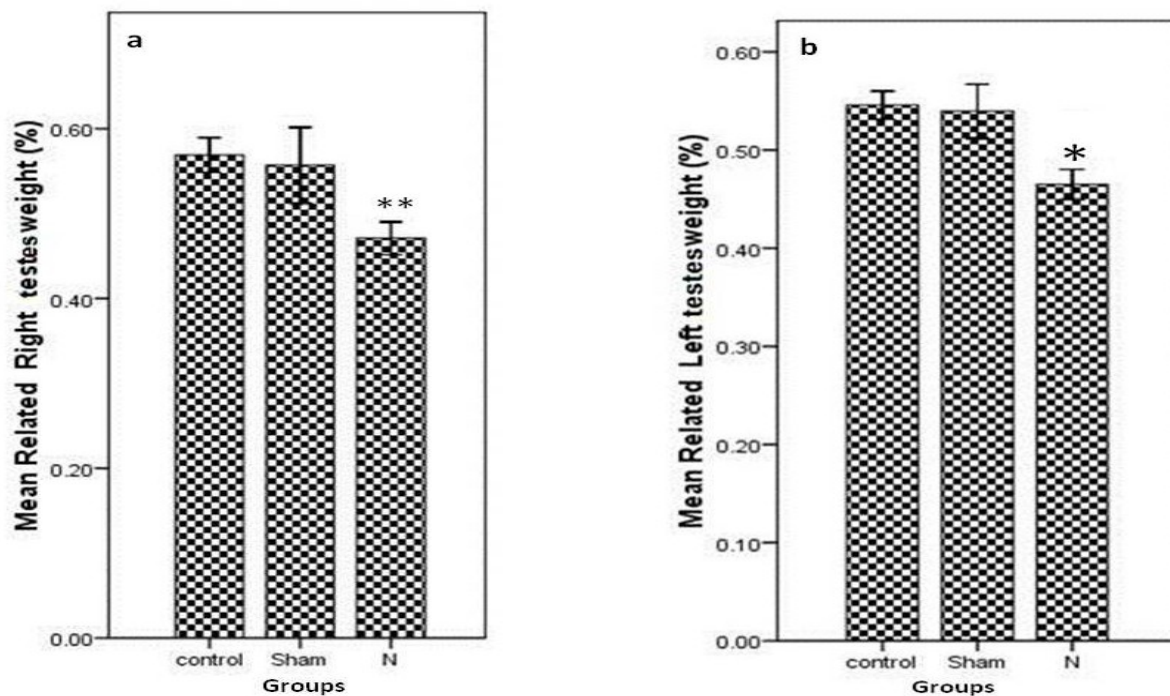


Figure2. Comparison of testes weights among the Control, Sham and N (experiment) groups. (a) Right testes weight. (b) Left testes weight. N is experiment group (nandrolone decanoate group). 10 rats were included in each group.

* $P < 0.001$: comparison between experiment and control groups.

** $P < 0.0001$: comparison of experiment and control groups.

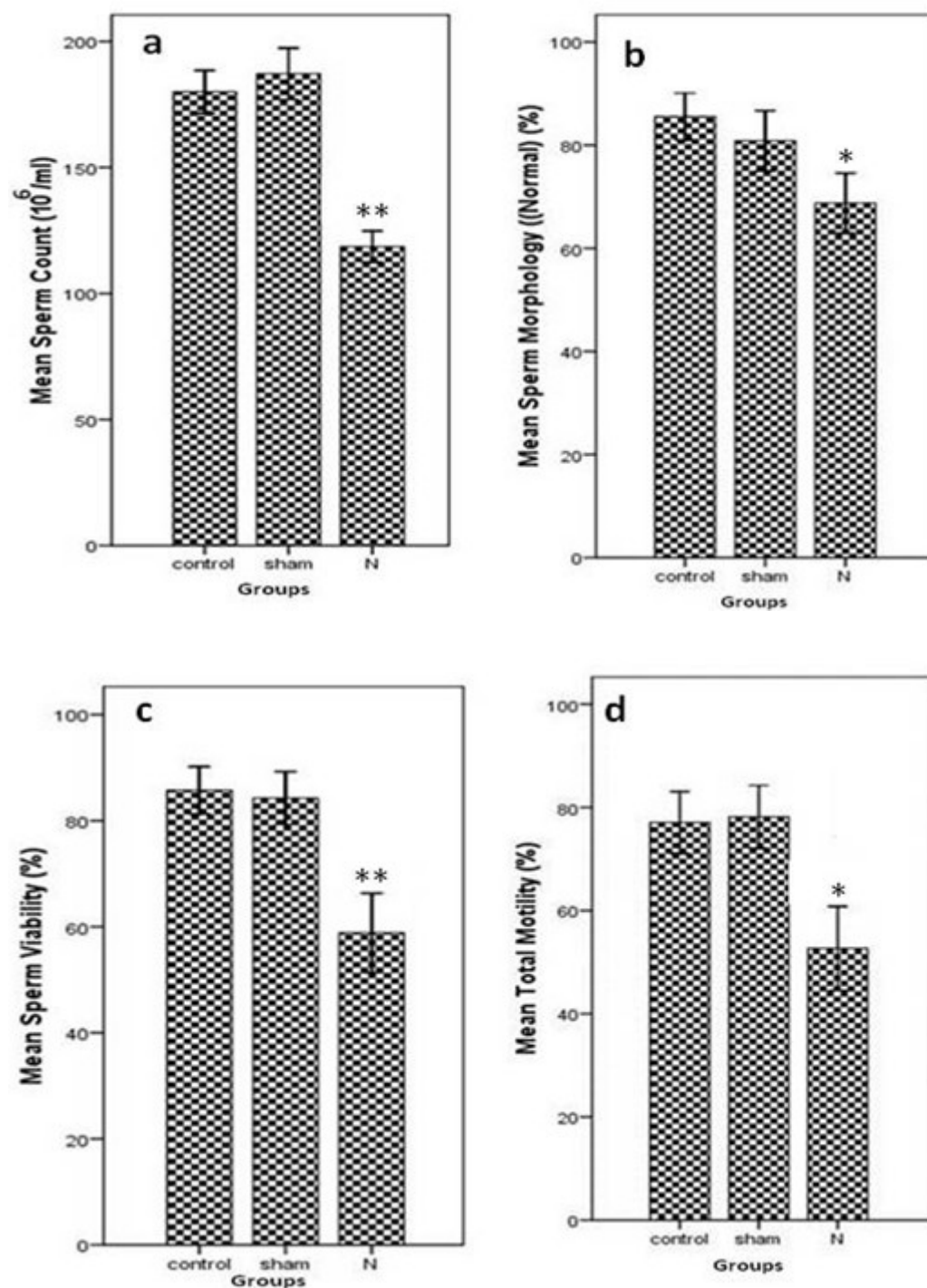


Figure 3. Comparison of sperm analysis results among three groups of Control, sham and N (experiment). (a) Sperm Count. (b) Sperm morphology. (c) Sperm viability. (d) Sperm motility. 10 rats were included in each group.

* $P < 0.001$: comparison between experiment and control groups.

** $P < 0.0001$: comparison of experiment and control groups.

Germ cell apoptosis by TUNEL test:

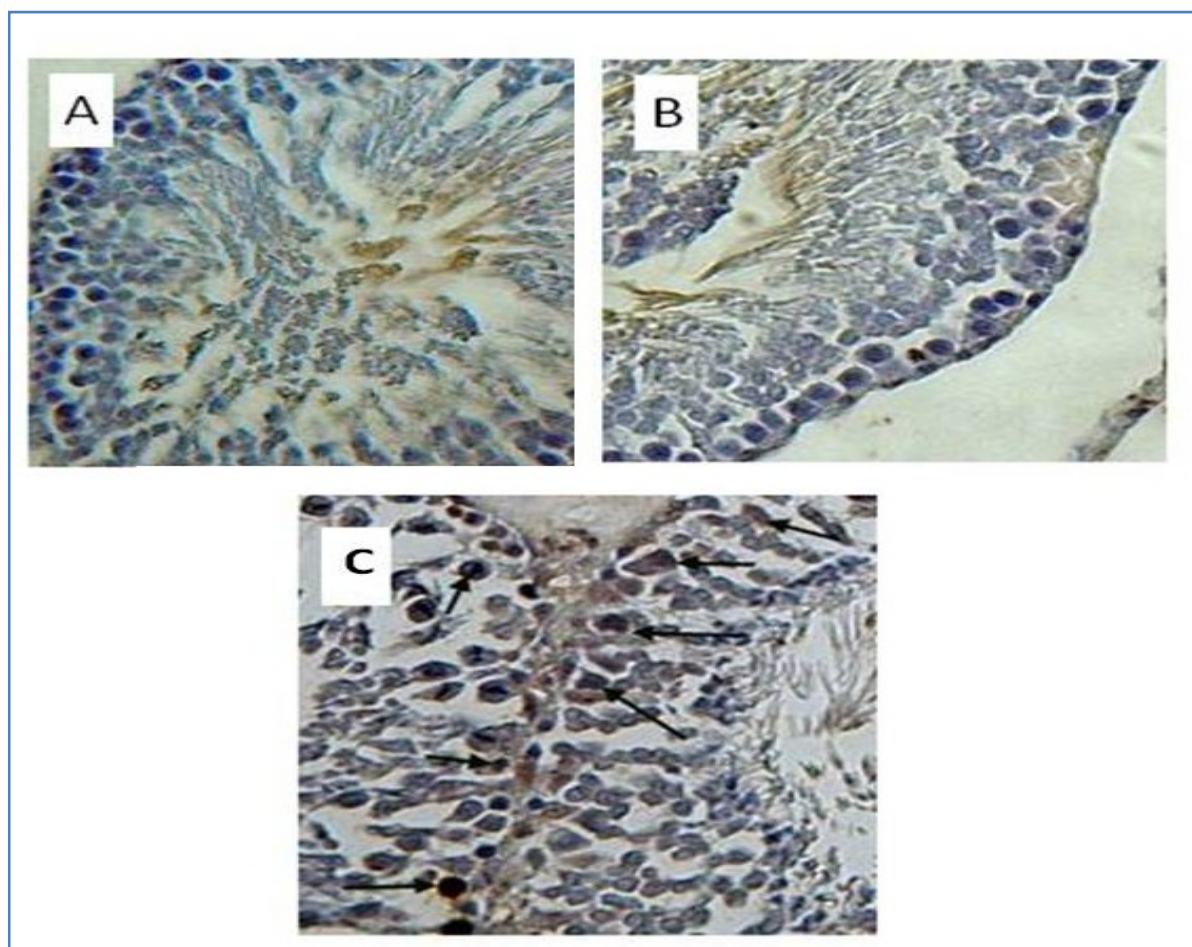
The number of normal germ cells was also evaluated (Table 1). There was a significant difference among the groups under study. On the basis of the results, the number of normal cells in experiment group was decreased compared with control group. Figure 4

represent data concerning germ cell apoptosis in studying groups. Treatment with nandrolone decanoate caused an increase in apoptosis of the cells (Figure 4C). In the control and sham groups, the number of apoptotic cells was not considerable (Figures 4A and 4B) (9).

Table 1. The number of normal germ cells in groups under study according to the TUNEL test.

Groups	P value
Control	9.4±0.22
Sham	9.6±0.31
Experiment	7.1±0.12*

* P<0.01, comparison of experiment and sham groups with control group.



Figures4. Immunohistochemical staining of testes in the groups under study. Comparison of germ cell apoptosis in groups A (Control), B (sham) and C (experiment). Dark brown cells (arrow) show the apoptotic cells (TUNEL test, ×200).

Discussion

One of the most prominent effects of AAS is the negative impact on the pituitary-gonad axis. AAS stimulates hypogonadotrophic and hypogonadism coupled with decreased serum testosterone concentrations (6). Shokri et al. showed that the suppression of sperm output is attributed to the degree of inhibition of germ cell development which is related to the degree of FSH, LH and testosterone suppression. Long-term AAS administration results in reduced testicular weight, testicular atrophy and abnormal morphology (10). AAS maximizes the anabolic effects, so the possibility of oxidative stress condition could increase (11). Consequently, metabolism of high doses of nandrolone decanoate by cytochrome P450 mono-oxygenases would have increased greatly the production of ROS resulting in a state of oxidative stress and up-regulation of the activity of the antioxidant enzymes such as SOD (1). To our knowledge, the exact mechanism through which the intramuscular injection of nandrolone decanoate could lead to free radical production is unidentified at present. Sperm DNA fragmentation could be due to several reasons such as insufficiency in recombination during spermatogenesis. Exposure of mature spermatozoa to excessive levels of ROS produced by immature sperm during migration from the seminiferous tubules to the epididymis could also lead to fragmented DNA (6). In accumulation, abnormal spermatogenic

maturation could result in DNA-fragmented sperm. Androgen action in the testis, as in other tissues, is mediated through androgen receptor (AR) transcriptional activation (7). Inside Sertoli cells, testosterone is selectively bound to the androgen receptor and activation of the receptor will result in initiation and maintenance of the spermatogenic process and reserve of germ cell apoptosis (7). In testes, ARs are expressed in the somatic Leydig, peritubular myoid and Sertoli cells as well as to rate testis, the epithelial cells of the epididymis, and prostate (1). We aimed to investigate whether prolonged treatment of rats with high dose of nandrolone decanoate modified oxidative stress markers through studying result of apoptotic change. In addition, it was found that loss of AR activity from Sertoli cells would lead to spermatogenic failure resulting in incomplete meiosis and collapse to transition of spermatocytes to haploid round spermatids (6) Sertoli cells play an important role in organizing the somatic cell lineages and in formative the structure of the testis (12); they also support a finite number of germ cells, and thus, their number determines the spermatogenic capacity of the adult (13,14). The actions of nandrolone decanoate were receptor and dose dependent; the more drug injected the more adverse the side effect. When nandrolone decanoate acts in a receptor mediated mode, we can assume that the high concentration of

nandrolone decanoate injected to rats can overcome the fact that AR has low similarity to nandrolone decanoate (6). In our study we indicated that the effects of nandrolone decanoate injection on level of sperm DNA fragmentation and sperm concentration early maturation arrest were receptor dependent. AAS are commonly used in our society, and physicians should be conscious of their physiological effects. In calculation, nandrolone decanoate treatment caused testosterone depression, enhanced lipid peroxidation, as well as severe fragmentation in the DNA of sperm of treated rats. Although the concentration of nandrolone decanoate which was administered to male rats is comparable to what is injected by AAS abusers, we are aware that caution should be taken

when such results are extrapolated from animal to human being (7). However, it is possible that the basal level of the circulating endogenic androgen will play a role, as previously described (13).

In conclusion, this study revealed that the treatment of rats with suprapharmacologic dose of nandrolone decanoate during eight weeks does promote ergogenic effects on male reproductive system and increased apoptotic change on spermatogenic line cells which in turn affects the fertility parameters.

Acknowledgment

This study was supported financially by Tehran University of medical sciences and we gratefully thank for their valuable help in this research.

References

1. Minaii B, Moayeri A, Shokri S, Melatonin Improve the Sperm Quality in Forced Swimming Test Induced Oxidative Stress in Nandrolone Treated Wistar Rats. *Acta Med Acad.* 2014;52(7):496-504
2. Bahrke MS, Yesalis CS. Abuse of anabolic androgenic steroids and related substances in sport and exercise. *Curr Opin Pharmacol.* 2004;4(6):614-20.
3. Clark AS, Harrold EV, Fast AS. Anabolic-androgenic steroid effects on the sexual behavior of intact male rats. *Horm Behav.* 1997;31(1):35-46.
4. Torres-Calleja J, Gonzalez-Unzaga M, DeCelis-Carrillo R, Calzada-Sanchez L, Pedron N. Effect of androgenic anabolic steroids on sperm quality and serum hormone levels in adult male bodybuilders. *Life sci.* 2001;68(15):1769-74
5. Lubna H, Tahtamouni A, Noor H. Mustafa A, Iman M. Hassan A, Iman M, Ahmad A. Nandrolone Decanoate administration to male rats induces oxidative stress, seminiferous tubules abnormalities, and sperm DNA fragmentation. *Jordan J Biol Sci.* 2010; 3(4): 165-74.
6. Shokri S, Aitken RJ, Abdolvahhabi, Abolhasani F. Exercise and supraphysiological dose of nandrolone deconoate increase apoptosis in spermatogenic cells. *Basic Clin Pharmacol Toxicol.* 2010;106(4):324-30.

7. Shokri S, Hemadi M, Bayat G, Bahmanzadeh M. Combination of running exercise and high dose of anabolic androgenic steroid, nandrolone decanoate, increases protamine deficiency and DNA damage in rat spermatozoa. *Andrologia*. 2013; 46(2):184-90.
8. Weikert S, Schrader M, Müller M, Schulze W. Expression levels of the inhibitor of apoptosis survivin in testes of patients with normal spermatogenesis and spermatogenic failure. *Fertil Steril*. 2005;83(4):1100-5.
9. Elmore S. Apoptosis: a review of programmed cell death. *Toxicol Pathol*. 2007;35(4):495-516.
10. Seed J, Chapin RE, Clegg ED, Dostal LA, Foote RH, Hurtt ME, et al. Methods for assessing sperm motility, morphology, and counts in the rat, rabbit, and dog: a consensus report. *Reprod Toxicol*. 1996;10(3):237-44.
11. Lubna TH, Mustafa H Noor , Hassan M Iman , Ahmad M Iman. Nandrolone Decanoate administration to male rats induced oxidative stress, seminiferous tubules abnormalities, and sperm DNA fragmentation. *Biol Sci*. 2010;3:J165-74
12. O'sullivan AJ, Kennedy MC, Casey JH, Day RO. Anabolic-androgenic steroids: medical assessment of present, past and potential users. *Med J Australia*. 2000;173(6):323-7.
13. Nooraf SHan A, Karbalay-Doust S, Ardekani FM. High doses of nandrolone decanoate reduce volume of testis and length of seminiferous tubules in rats. *APMIS*. 2005;113(2):122-5.
14. Montoto LG, Magaña C, Tourmente M, Martín-Coello J, Crespo C, Luque-Larena JJ, et al. Sperm competition, sperm numbers and sperm quality in murine rodents. *PloS One*. 2011;6(3):e18173.