

The Impact of Aerobic Exercise and Psilocybin on Methamphetamine-Induced Histopathological Changes in Rat Cerebral Cortex

Fariba Rasannezhad¹ , Asiéh Abbassi-Dalooi¹ ✉, Seyyed Javad Ziaolhagh² , Ahmad Abdi¹ 

¹ Department of Sport physiology, Ayatollah Amoli Branch, Islamic Azad University, Amol, Iran

² Department of Sport physiology, Shahrood Branch, Islamic Azad University, Shahrood, Iran

Article Info

Article type:

Research article

Article History:

Received: Apr. 29, 2023

Revised: Jul. 02, 2023

Accepted: Aug. 17, 2024

Published Online: Nov. 05, 2024

✉ Correspondence to:

Asiéh Abbassi-Dalooi
Department of Sport
physiology, Ayatollah Amoli
Branch, Islamic Azad
University, Amol, Iran

Email:

Abbasi.dalooi@gmail.com

ABSTRACT

Introduction: Methamphetamine addiction is one of the most prevalent substance use disorders. Augmenting traditional drug treatments with non-pharmacological interventions can enhance treatment efficacy and sustainability. This study aims to investigate the impact of aerobic exercise and psilocybin on histopathological changes in the cerebral cortex of methamphetamine-induced rats.

Material & Methods: This experimental research involved 30 female rats randomly allocated into five groups: control, methamphetamine, methamphetamine + aerobic exercise, methamphetamine + psilocybin, and methamphetamine + psilocybin + aerobic exercise. Rats received 15 mg of methamphetamine intraperitoneally every 12 hours for four days. Aerobic exercise was conducted on a treadmill with an 8-week program of escalating intensity, reaching a maximum running time of 30 minutes and speed of 25 m/min, with a 5% slope introduced in the fourth week. Psilocybin was administered intraperitoneally at a microdose of 0.025 mg/kg over 24 sessions. Histopathological changes were assessed using hematoxylin and eosin staining, and descriptive analysis with images was employed to interpret cortical brain tissue samples.

Results: Histological examination revealed tissue and cellular disorganization, altered morphology of pyramidal neurons, and reduced microglial cell counts in methamphetamine-induced rats compared to controls. Endurance training, psilocybin supplementation, and their combination exhibited improvements in tissue and cellular alterations in the cerebral cortex of addicted rats.

Conclusion: This study demonstrates that exercise training and psilocybin administration in methamphetamine-exposed rats ameliorate cortical histopathology, with the combined intervention yielding the most significant effects. This synergistic effect may reduce the risk of relapse in methamphetamine users by positively modulating brain and central nervous system functions.

Keywords: Methamphetamine, Aerobic Exercise, Psilocybin, cerebral Cortex, Rats

➤ How to cite this paper

Rasannezhad F, Abbassi Dalooi A, Ziaolhagh SJ, Abdi A. The Impact of Aerobic Exercise and Psilocybin on Methamphetamine-Induced Histopathological Changes in Rat Cerebral Cortex. J Bas Res Med Sci. 2024; 11(1):68-78.

Introduction

Drug addiction is one of the current problems of human society. This long-standing problem affects the majority of countries, and the use of narcotics and psychotropic drugs has increased day by day in almost all societies, so that the last few decades have been called the age of drugs. On the other hand, there is a high positive correlation coefficient between drug use and committing a large number of other anti-social behaviors, which inflicts many blows on the fabric of society (1). One of the most widely used drugs is methamphetamine addiction, and it is estimated that there are about 15-16 million users worldwide. The reasons for using this narcotic drug include its easy production, easy access, and cheapness (2). The pharmacological mechanism that affects these diverse functions is not well known, but methamphetamine mainly affects the central nervous system. It interrupts the reabsorption of dopamine and other single amine neurotransmitters and also facilitates the release of these single amines into the synaptic space (3). Short-term use of this narcotic drug causes a feeling of happiness, increased energy, reduced fatigue, reduced appetite, and increased libido (4). Its long-term use also causes chemical changes in neurons and ultimately leads to permanent damage to the brain, especially in the structures that contain dopaminergic neuron endings, which also participate in perceiving and emotional problems. Studies show that this drug causes a decrease in the ability of stem cells to reproduce and regenerate in special parts of the brain. They also change the path of their differentiation from the normal path to abnormal paths and also change the process of development, growth, and differentiation of stem cells or neural progenitors (5). The multidimensionality and complexity of the factors involved in addiction to these narcotics necessitate the need for multifaceted and long-term treatment. It seems that relying on one treatment method does not work in the treatment of these patients (6). Recent clinical developments promise the use of psilocybin in the treatment of

mental disorders such as depression, addiction, and obsessive-compulsive disorder. Psilocybin is a psychoactive substance whose metabolite, psilocybin, is a 5-HT_{2A} receptor agonist (7). Recently, it has been found that psilocybin (4-phosphoryloxy-N, N-dimethyltryptamine), which is a natural hallucinogen and a major compound in *umbelliferae*, has significant effects (8, 9). Awareness and use of mushrooms for depression and resulting improved quality of life are growing. The appropriate dose for most people ranges from 1 to 3.5 grams of dried mushrooms or 10 to 15 grams of fresh mushrooms. Psilocybin mushrooms sometimes increase heart rate and blood pressure in people (10). Psilocybin induces various physical and psychological symptoms by stimulating the sympathetic nervous system. Like many psychedelic substances, the effects of psychedelic mushrooms are subjective and can vary considerably between individuals (11). Gotvaldová et al.'s study demonstrates that even a single high dose of psilocybin can lead to long-term changes in the user's personality (12). In Nikadimanj et al.'s research, the immune effects of psilocybin magic mushroom extract on endothelin-induced hypertrophy and cell damage in cardiomyocytes were investigated. The results indicated that aqueous extracts of psilocybin did not exacerbate the pathological hypertrophy induced by endothelin-1 (13).

On the other hand, physical exercise could be beneficial in addiction treatment because it shares a common neural circuit with addictive drugs (14). Exercise intervention has been shown to reduce drug dependence in patients with amphetamine addiction by improving dopamine levels and immunity while decreasing negative emotions (15). Today, exercise is recognized as one of the most effective and crucial factors in promoting mental and emotional stability in individuals. It can also exert positive effects on behavior. Aerobic exercise significantly increases the length of nerve terminal branches and helps maintain the normal size of the end plate (16).

Physical exercise (PE) promotes neuronal survival and neuroplasticity and optimizes neuroendocrine and physiological responses to psychosocial and physical stress. PE sensitizes the parasympathetic nervous system (PNS), Autonomic Nervous System (ANS), and central nervous system (CNS) by facilitating processes such as synaptic plasticity, neurogenesis, angiogenesis, and autophagy (17, 18).

To date, the detailed role of psilocybin and its potential effects on the cerebral cortex remain undetermined. Additionally, the effects of amphetamine in combination with these two exercises are not fully understood. Therefore, this research aims to investigate the effect of aerobic exercise and psilocybin on the histopathological changes of the cerebral cortex in rats induced with methamphetamine.

Materials and methods

The present research is experimental in nature. Rats were sourced from Shahrood University of Medical Sciences, with an initial weight range of 140-160 grams. Upon arrival, each animal underwent a quarantine period of one to ten days to ensure health and acclimation. Rats were excluded from the study if their weight exceeded 190-200 grams, as this weight range was necessary to induce amphetamine effects.

Individual rats were housed in separate cages, provided with daily access to water and food. Thirty female rats were randomly assigned to five groups, each comprising eight rats: the control group (receiving injections of normal saline), the methamphetamine group, the methamphetamine + aerobic exercise group, the methamphetamine + psilocybin group, and the methamphetamine + aerobic exercise + psilocybin group.

Rats were maintained under controlled environmental conditions, including temperature, humidity, and a regulated light/dark cycle, with ad libitum access to water and specialized laboratory animal food. All interventions were conducted following the guidelines for working with laboratory animals of Islamic Azad University. The research protocol was reviewed and approved by the ethics committee under the code IR.IAU.AMOL.REC.1401.104.

Dose of methamphetamine and psilocybin

Two doses were used to induce addiction by methamphetamine. A lower dose was given over 4 days, followed by a higher dose over 5 days, every 12 hours according to the reference. The dose of methamphetamine was injected intraperitoneally in the amount of 15 mg (19). Additionally, psilocybin was injected intraperitoneally in the form of a microdose of 0.025 mg/kg during 24 sessions (10).

Exercise program

After the methamphetamine induction was completed, the psilocybin injections were administered first, followed by scheduled exercise sessions. The aerobic exercise protocol was conducted on a treadmill. The training regimen spanned over 8 weeks with increasing intensity. The total running time progressed from 20 minutes to 30 minutes. The maximum daily speed was gradually raised from 20 m/min to 25 m/min, and during the fourth week, a 5% slope was introduced (20). Exercise sessions were conducted between 8-10 AM (Table 1).

Table 1. Endurance Training Protocol.

Practice factors	Compatibility	First week	Second week	Third week	Fourth week	Fifth week	Sixth week	Seventh week	Eighth week
Treadmill speed (m/min)	8-10	20	20	20	20	25	25	25	25

The slope of the treadmill (%)	0	0	0	0	5	5	5	5	5
Training time per session (minutes)	15	20	20	25	25	25	25	30	30
Repeat session (in a week)	5	3	3	3	3	3	3	3	3

Open field tests, habituation, Y-shaped maze, passive inhibitory avoidance test, platform avoidance test, Morris water maze, active avoidance test, radial maze, eight-arm maze, and object recognition test were employed to assess the behavioral data.

Sampling and histopathological examination

The samples were anesthetized under completely similar conditions, 48 hours after the last training session and after 12 to 14 hours of fasting, with a combined intraperitoneal injection of ketamine (60 mg/kg) and xylazine (5 mg/kg). The prefrontal part of the cerebral cortex tissue was weighed and washed with saline immediately after isolation. Then it was placed in tubes to prevent destruction and transferred to liquid nitrogen and then stored in a refrigerator at -80°C until the time of measurement. Adhering to ethical standards for animal welfare, the target tissue was fixed in 10% formalin solution and then prepared for histological analysis. Slices were stained with hematoxylin and eosin and examined. An optical microscope was utilized to evaluate the prepared sections, and images were captured from all slides.

The evaluated variables in the cerebral cortex tissue included changes in neurons, neuroglial tissue, gray matter, white matter, and microglia. The intensity and degree of these changes were determined based on microscopic observations and photomicrograph preparation. In each slide, under the microscope and with magnification, at least 400 fields were observed and photographed. In each area, the degree of cellular and tissue changes was graded from 0 to 3, where grade 0 indicates no observed changes, grade 1 indicates mild changes, grade 2 indicates moderate changes, and grade 3 indicates severe changes.

The cerebral cortex tissue was observed using an Olimius optical microscope with magnifications of 40x, 100x, and 400x, with at least 3 to 9 fields examined. Histological results obtained from cortical brain tissue samples were described descriptively with accompanying images.

Results

The histological results obtained from the cortical brain tissue samples of the tested groups are presented in figure 1 and table 2.

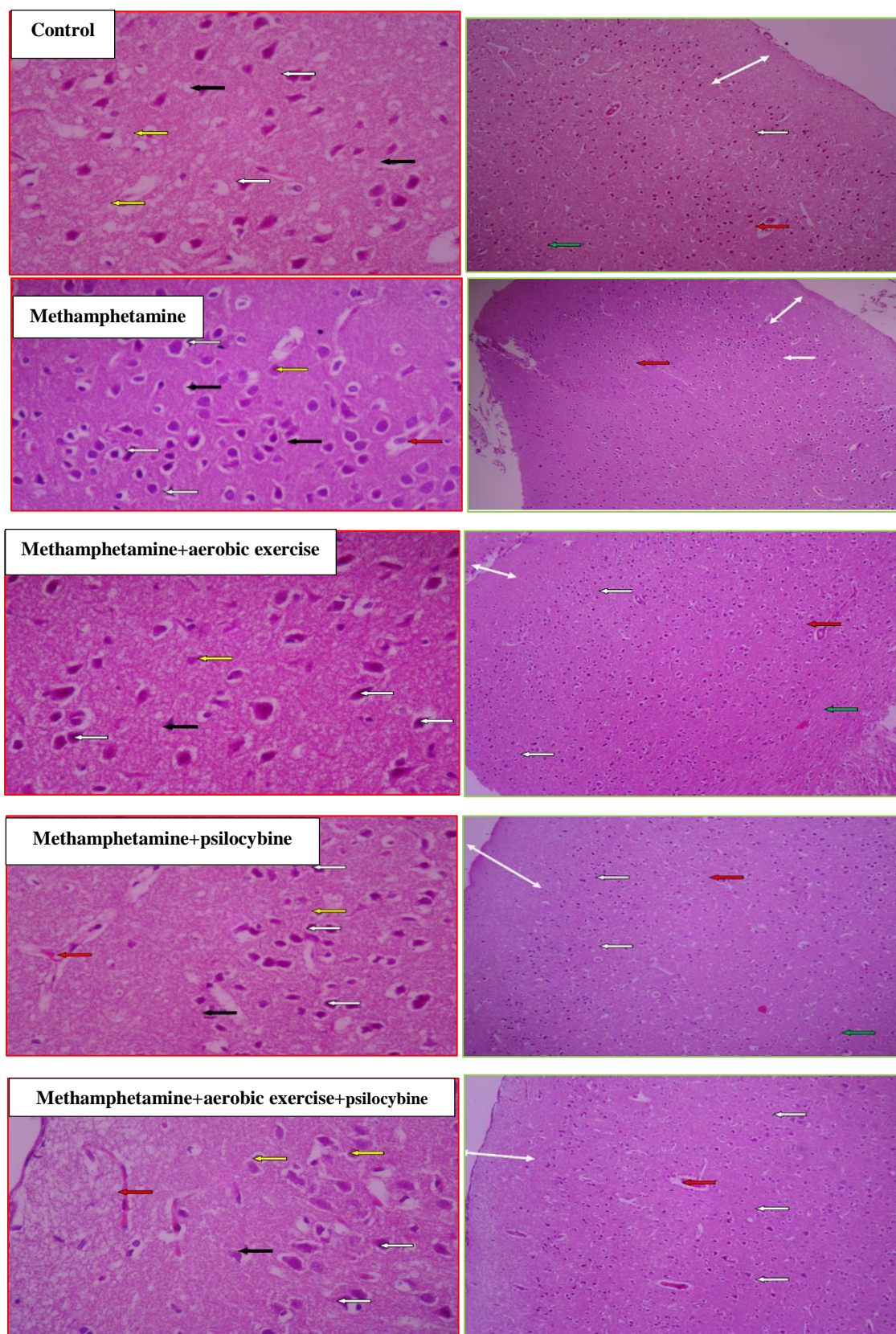


Figure 1. Histopathology of the frontal part of the brain cortex in various research groups. (**Left:** Hematoxylin and eosin staining, magnification x400. **Right:** Hematoxylin and eosin staining, magnification x100).

In the samples of the control group, no changes are observed in the cortical tissue of the brain and its layers, and the tissue characteristics are completely regular. The gray matter has a suitable size, and its first layer, which is located under the soft tissue, is called molecular and is associated with a small number of nerve cells and many nerve fibers (double-sided white arrow). The deep layer of tissue is called white matter, which has nerve support cells (green arrow). Neurons, which are the main cells of the nervous tissue, are seen in the cerebral cortex in the form of pyramids, with their apex towards the cortex and their base towards the white matter (white arrow). Neuroglial cells, which are the supporting tissue of the nerves, are distributed in all areas equally and with normal numbers, and they often have dark cytoplasm and clear and clear nuclei (yellow arrow). Microglia cells, which are responsible for xenophagy in the tissue, are seen with dark and elongated nuclei and in appropriate numbers in all areas (black arrow). Blood vessels and blood-brain barrier can also be seen with normal characteristics (red arrow).

In the samples of the methamphetamine group, in the cortical tissue of the brain, compared to the control group, changes such as disintegration and disorganization are observed in some areas. The gray matter has irregular cells with improper distribution, and a molecular layer with a smaller size can be seen on its surface (double-sided white arrow). The white material has a small size and an inappropriate texture. Neurons are also scattered and have an inappropriate shape and often have a degenerate state with a dark and indistinct nucleus (white arrow). Microglia cells are small, and their number and distribution are not suitable (black arrow). Neuroglial cellular characteristics (yellow arrow) and blood barrier (red arrow) are normal and unchanged.

In the samples of the methamphetamine group who have received sports activity, the cortical tissue of the brain and its related layers have proper order and

organization, and the amount of disintegration has decreased. The characteristics of gray matter and molecular layer (double-sided white arrow), and white matter (green arrow) and their size are reported to be almost normal. But the changes in neurons are still evident. It is also associated with indistinct cytoplasm and nucleus and reduced size (white arrow). So that most of the neurons are seen with these characteristics. Microglia cells have a small number and abnormal cytoplasm (black arrow). Characteristics of supporting cells or neuroglial cells (yellow arrow) as well as normal blood vessels (red arrow) are reported.

In the samples of the methamphetamine group that received psilocybin, the cortical tissue of the brain showed minimal changes compared to the control group. The gray matter and the molecular layer (double-sided white arrow) exhibited slight alterations in size and cellular characteristics. The white matter (green arrow) maintained the appropriate size, distribution, and cell count. Neuronal cellular features were marked by increased cytoplasmic coloration and irregular shape, along with reduced cell size (white arrow). Microglia cells were present in a reduced number and displayed inappropriate distribution, although their cellular characteristics were deemed normal (black arrow). The characteristics of neuroglial cells (yellow arrow) and the attributes of blood vessels and the blood-brain barrier were consistent with those of the normal control group (red arrow).

In the samples of the methamphetamine group that received aerobic training and psilocybin, the cortical tissue of the brain exhibited slight tissue alterations compared to the control group. Nonetheless, proper order, cohesion, and cell dispersion were noted. The general characteristics of the gray matter as well as the molecular layer (double-sided white arrow) and the natural white matter (green arrow) were observed with suitable texture and precise location under the soft tissue. Neuronal cell characteristics (white arrow) still displayed alterations, including

cytoplasmic darkness. However, the number and shape of cells in the neuroglial tissue were reported to be completely normal (yellow arrow). Microglia cells also exhibited proper shape compared to the control group, although their number remained

lower than normal (black arrow). The characteristics of the blood-brain barrier were normal, but slight dilatation of the blood vessels was observed (red arrow).

Table 2. Number (Percentage) of Severity of Psychological Symptoms.

Group	Neuron	Neuroglial tissue	Gray matter	White matter	Microglia
Control	0	0	0	0	0
Methamphetamine	2	0	1	1	2
Methamphetamine and aerobic exercise	2	0	1	1	1
Methamphetamine and psilocybin	2	0	1	0	1
Methamphetamine and aerobic exercise and psilocybin	1	0	1	0	1

The observed changes are graded from 0 to 3, with Grade 0 indicating no change, Grade 1 indicating mild changes, Grade 2 indicating moderate changes, and Grade 3 indicating severe changes.

Discussion

The present study aimed to investigate the effect of aerobic exercise and psilocybin on the histopathological changes of the cerebral cortex in rats induced with methamphetamine. The histopathology findings of the cerebral cortical tissue revealed that the samples of the methamphetamine group exhibited notable changes compared to the control group. These changes included cell disintegration and disorganization in some areas, irregular cells with inappropriate distribution in the gray matter, a smaller size of the molecular layer, and inappropriate tissue arrangement of the white matter. Additionally, dispersed and irregularly shaped neurons with often degenerate states, as well as small and inappropriately distributed microglia cells, were observed.

Conversely, aerobic exercise contributed to the improvement of the order and organization of the cortical tissue of the brain and reduced its disintegration compared to the samples of the

methamphetamine group. Furthermore, characteristics of gray matter, molecular layer, and white matter, including their sizes, as well as the characteristics of neuroglial cells and normal blood vessels, were observed. Therefore, it can be concluded that training has resulted in reducing the side effects of methamphetamine. In the addiction process, exercise typically mitigates the effects of substance abuse, which appears to be related to regular exercise intervention (21). Researchers have shown that both aerobic and anaerobic exercise improves brain function. Moreover, the combination of these two types of exercise resulted in significant improvement compared to aerobic exercise alone (22). Exercise is a potential non-pharmacological treatment that operates through a similar system in the early and late stages of the addiction process. Evidence has shown that both physical exercise and addictive drugs activate shared reward neural circuits and modify different neurotransmitter systems. The dopaminergic system, which plays a central role in addiction, is the main modified neurotransmitter system (14). Mental status, drug

craving, immune function, and quality of life of patients with amphetamine addiction improve after exercise intervention (15). Exercise has been shown to activate brain reward pathways (23). Therefore, it may regulate the initiation of substance abuse and moderate the development of addiction (26). It has also been reported that exposure to methamphetamine can reduce the proliferation and survival of medial prefrontal cortex progenitors, and that exercise has a protective effect against it (24). Moderate-intensity aerobic exercise reduces drug craving in methamphetamine-dependent subjects and helps identify drug-related and natural inhibitory controls (25). Park et al. (26) showed that exercise in the form of wheel running (after methamphetamine exposure in rats) protected against methamphetamine-induced changes in neurogenesis. Antioxidant effects have also been observed in people who did regular aerobic exercise (27). This is consistent with the effects of physical exercise that improves redox balance in the CNS by enhancing antioxidant defense mechanisms (28). In addition, Speck et al. (29) showed that a sufficient frequency of moderate-intensity treadmill exercise induced antioxidant changes in the rat hippocampus. In a recent study, exercise reduced methamphetamine-induced oxidative stress in brain microvessels. In such a way, by increasing the antioxidant capacity of these capillaries, it protected against disorder in mice (30).

Another result of the present study was the improvement of the histopathology of cerebral cortical tissue due to the use of psilocybin and the combination of exercise with psilocybin in rats consuming methamphetamine. In recent years, there has been scientific reconsideration of the potential use of psilocybin and other psychoactive substances for the treatment of psychiatric disorders, particularly mood disorders, anxiety, and addiction (31).

In patients with mood depression and anxiety disorder, psilocybin was effective in reducing

depressive symptoms in short-term, medium-term, and long-term analysis. Antidepressant activity lasted longer than psychoactive effects. However, the quality of the acute psychotic experience significantly influenced treatment outcomes (14). The most important pharmacological property that psilocybin showed in all trials was the rapid onset of the antidepressant effect. This effect can be enhanced when used in combination with traditional antidepressant treatment, which has a long latency (32). The effects of psilocybin appear to be both biological and context-dependent (10). Since psilocybin exhibits potent effects similar to other antidepressants in rats and demonstrates long-term antidepressant effects to reduce depressive symptoms in humans, this aspect became the foundation of its antidepressant effects. In humans, it manifests as a biological process, while it correlates with an antidepressant effect. These biological processes may include cell proliferation, increased synaptic connectivity, and anti-inflammatory effects. Drugs such as psilocybin have been shown to induce these types of changes in clinical models, and each of these physiological effects is associated with antidepressant-like behavioral outcomes (33). Psilocybin shares properties similar to lysergic acid diethylamide (LSD) and mescaline, albeit with a slightly different chemical structure. A small percentage of psilocybin is present in most mushroom species, with this amount roughly equivalent to 1-2 grams of dried mushrooms. Its focus has been on mental health conditions with abnormalities in sensory perception, such as depressive and anxiety disorders or anxiety-related disorders (34). The findings support the idea that psilocybin has the potential to normalize limbic hyperactivity in people with depressed mood. Despite strong evidence that activation of 5-HT_{2A} receptors is necessary to mediate the action of psilocybin, psilocybin, the bioactive metabolite of psilocybin, also activates 5-HT_{1A} and 5-HT_{2C} receptors. Serotonergic neurons originate in the raphe nuclei of the brainstem and release 5-HT in terminal nerve endings in efferent regions such as

the amygdala. In the amygdala, both 5-HT_{1A} and 5-HT_{2A} receptors are abundant and located on gamma-aminobutyric acidergic neurons that inhibit postsynaptic cell firing. Thus, 5-HT receptor stimulation in the amygdala may indirectly inhibit the amygdala response through activation of postsynaptic 5-HT receptors. Considerable evidence suggests that increased serotonergic tone in the amygdala is a critical mechanism underlying the acute effects of psilocybin. Therefore, it may increase the speed of serotonergic neurotransmission in the amygdala by creating combined 5-HT_{1A/2A} agonists (35). According to the results of the present research, the use of psilocybin can prevent tissue changes in the cerebral cortex of mice induced by methamphetamine. Therefore, it can be concluded that the consumption of psilocybin had a positive protective role in preventing the side effects of methamphetamine in the cerebral cortex tissue. Also, the histopathological findings in the samples of the methamphetamine group that received aerobic exercise and psilocybin compared to the control group do not show any specific changes in the whole tissue and only show a few neuronal changes. According to the mentioned cases, the beneficial effects of sports activity and psilocybin on the improvement of histopathology in the cortex of female rats using methamphetamine were evident. Also, the best results were obtained when they were used simultaneously, which shows the synergistic effect of exercise and psilocybin. Nevertheless, according to the few studies conducted in this field, research on the protective effect of aerobic exercise along with psilocybin supplementation on neurological factors in samples addicted to methamphetamine needs more research.

Conclusion

In general, the results of the present study indicate that exercise training and psilocybin in rats consuming methamphetamine led to an improvement in histopathology in the cortex of female rats. The best results were obtained in the combined group of exercise and psilocybin,

highlighting the synergistic effect of these two interventions. These changes may reduce the likelihood of relapse in methamphetamine users by providing positive effects on the brain and central nervous system.

Acknowledgements

This article is excerpted from the doctoral thesis in sports physiology, approved by Islamic Azad University, Ayatollah Amoli branch. The authors would like to express their gratitude to all those who contributed to the progress of this work.

Financial support

This research was conducted with personal funding from the researcher.

Conflict of interest

The authors of this study declare no conflicts of interests.

Authors' contributions

FR: original draft, methodology. **AAD:** writing, review and editing, project management. **JZ:** Methodology. **AA:** Analysis.

References

- Benthin A, Slovic P, Severson H. A psychometric study of adolescent risk perception. *J Adolesc.* 1993; 16(2):153-68. <https://doi.org/10.1006/jado.1993.1014>
- Krasnova IN, Cadet JL. Methamphetamine toxicity and messengers of death. *Brain Res Rev.* 2009; 60(2):379-407. <https://doi.org/10.1016/j.brainresrev.2009.03.002>
- Fleckenstein AE, Volz TJ, Riddle EL, Gibb JW, Hanson GR. New insights into the mechanism of action of amphetamines. *Annu. Rev. Pharmacol. Toxicol.* 2007; 47:681-98. <https://doi.org/10.1146/annurev.pharmtox.47.120505.105140>
- Barr AM, Panenka WJ, MacEwan GW, Thornton AE, Lang DJ, Honer WG and et al. The need for speed: an update on methamphetamine addiction. *J Psychiatr Neurosci.* 2006; 31(5):301-13. <https://www.jpn.ca/content/31/5/301.short>
- Baptista S, Lasgi C, Benstaali C, Milhazes N, Borges F, Fontes-Ribeiro C and et al. Methamphetamine decreases dentate gyrus stem cell self-renewal and shifts the differentiation towards neuronal fate. *Stem Cell Res.* 2014; 13(2):329-41. <https://doi.org/10.1016/j.scr.2014.08.003>
- Mokri A. Brief overview of the status of drug abuse in Iran. 2002. [file:///C:/Users/u/Downloads/86920020312%20\(3\).](file:///C:/Users/u/Downloads/86920020312%20(3).)
- Huang Z, Wei X, Wang Y, Tian J, Dong J, Liang B and et al. Psilocybin Promotes Cell-Type-Specific Changes in the Orbitofrontal Cortex Revealed by Single-Nucleus RNA-seq. *bioRxiv.* 2024; 2024-01. <https://doi.org/10.1101/2024.01.07.573163>.
- Nkadimeng SM, Nabatanzi A, Steinmann CM, Eloff JN. Phytochemical, cytotoxicity, antioxidant and anti-inflammatory effects of *Psilocybe natalensis* magic mushroom. *Plants.* 2020; 9(9):1127. <https://doi.org/10.3390/plants9091127>
- Zanikov T, Gerasymchuk M, Ghasemi Gojani E, Robinson GI, Asghari S, Groves A, Haselhorst L, Nandakumar S, Stahl C, Cameron M, Li D. The Effect of Combined Treatment of Psilocybin and Eugenol on Lipopolysaccharide-Induced Brain Inflammation in Mice. *Molecules.* 2023 Mar 14;28(6):2624. <https://doi.org/10.3390/molecules28062624>.
- Nkadimeng SM, Hay L, Steinmann CM, Eloff JN. Administration effects of four psilocybin mushroom extracts on serotonin levels and endothelial nitric oxide synthase activity levels in vivo and in vitro after one hour. *J Inflamm Res.* <https://doi.org/10.21203/rs.3.rs-3088850/v1>
- Hibicke M, Landry AN, Kramer HM, Talman ZK, Nichols CD. Psychedelics, but not ketamine, produce persistent antidepressant-like effects in a rodent experimental system for the study of depression. *ACS Chem Neurosci.* 2020; 11(6):864-71. <https://doi.org/10.1021/acchemneuro.9b00493>
- Gotvaldová K, Hájková K, Borovička J, Jurok R, Cihlářová P, Kuchař M. Stability of psilocybin and its four analogs in the biomass of the psychotropic mushroom *Psilocybe cubensis*. *Drug Test Anal.* 2021; 13(2):439-46. <https://doi.org/10.1002/dta.2950>
- Nkadimeng SM, Steinmann CM, Eloff JN. Effects and safety of *Psilocybe cubensis* and *Panaeolus cyanescens* magic mushroom extracts on endothelin-1-induced hypertrophy and cell injury in cardiomyocytes. *Sci Rep.* 2020; 10(1):1-1. <https://www.nature.com/articles/s41598-020-79328-5>
- Rosa HZ, Barcelos RC, Segat HJ, Roversi K, Dias VT, Milanese LH, Burger ME. Physical exercise modifies behavioral and molecular parameters related to opioid addiction regardless of training time. *Eur Neuropsychopharmacol.* 2020 Mar 1;32:25-35. <https://doi.org/10.1016/j.euroneuro.2019.12.111>.
- He Q, Wu J, Wang X, Luo F, Yan K, Yu W, Mo Z, Jiang X. Exercise intervention can reduce the degree of drug dependence of patients with amphetamines/addiction by improving dopamine level and immunity and reducing negative emotions. *Am J Transl Res.* 2021;13(3):1779. <https://www.ncbi.nlm.nih.gov/pmc/articles/PMC8014419/>.
- Bahreini Pour MA. Investigation the effect of low-intensity aerobic training for 10 weeks along with blood flow restriction on amount of protein BDNF in soleus and EDL muscles as well as the sciatic nerve in aged male rats. *J Sport Exerc Physiol.* 2019; 12(1):59-75. <https://doi.org/10.52547/joeppa.12.1.59>
- Mahalakshmi B, Maurya N, Lee SD, Bharath Kumar V. Possible neuroprotective mechanisms of physical exercise in neurodegeneration. *Int J Mol Sci.* 2020 Aug 16;21(16):5895. <https://doi.org/10.3390/ijms21165895>.
- Fari G, Lunetti P, Pignatelli G, Raele MV, Cera A, Mintrone G, Ranieri M, Megna M, Capobianco L. The effect of physical exercise on cognitive impairment in neurodegenerative disease: from pathophysiology to clinical and rehabilitative aspects. *Int J Mol Sci.* 2021 Oct 27;22(21):11632. <https://doi.org/10.3390/ijms222111632>.
- Zhang KK, Wang H, Qu D, Chen LJ, Wang LB, Li JH and et al. Luteolin alleviates methamphetamine-induced hepatotoxicity by suppressing the p53 pathway-mediated apoptosis, autophagy, and inflammation in rats. *Front Pharmacol.* 2021; 12:641917. <https://doi.org/10.3389/fphar.2021.641917>
- Marques E, Vasconcelos F, Rolo MR, Pereira FC, Silva AP, Macedo TR and et al. Influence of Chronic Exercise on the Amphetamine-Induced Dopamine Release and Neurodegeneration in the Striatum of the Rat. *Ann N Y Acad Sci.* 2008; 1139(1):222-31. <https://doi.org/10.1196/annals.1432.041>
- Vieu T, Morais AP, Pasechnik R. Electroweak phase transitions in multi-Higgs models: the case of trinification-inspired THDSM. *J Cosmol Astropart Phys.* 2018; 2018(07):014. DOI: 10.1088/1475-7516/2018/07/014
- Alkadhi KA, Dao AT. Exercise decreases BACE and APP levels in the hippocampus of a rat model of Alzheimer's disease. *Mol Cell Neurosci.* 2018; 86:25-9. <https://doi.org/10.1016/j.mcn.2017.11.008>
- Brené S, Bjørnebekk A, Åberg E, Mathé AA, Olson L, Werme M. Running is rewarding and antidepressive. *Physiol Behav.* 2007; 92(1-2):136-40. <https://doi.org/10.1016/j.physbeh.2007.05.015>

24. Janse Van Rensburg K, Taylor A, Hodgson T, Benattayallah A. Acute exercise modulates cigarette cravings and brain activation in response to smoking-related images: an fMRI study. *Psychopharmacology*. 2009; 203:589-98. <https://link.springer.com/article/10.1007/s00213-008-1405-3>
25. Wang D, Zhu T, Zhou C, Chang YK. Aerobic exercise training ameliorates craving and inhibitory control in methamphetamine dependencies: a randomized controlled trial and event-related potential study. *Psychol Sport Exerc*. 2017; 30:82-90. <https://doi.org/10.1016/j.psychsport.2017.02.001>
26. Park M, Levine H, Toborek M. Exercise protects against methamphetamine-induced aberrant neurogenesis. *Sci Rep*. 2016; 6(1):34111. <https://www.nature.com/articles/srep34111>
27. Radak Z, Boldogh I. 8-Oxo-7, 8-dihydroguanine: links to gene expression, aging, and defense against oxidative stress. *Free Radic Biol Med*. 2010; 49(4):587-96. <https://doi.org/10.1016/j.freeradbiomed.2010.05.008>
28. Liśkiewicz A, Przybyła M, Park M, Liśkiewicz D, Nowacka-Chmielewska M, Małecki A and et al. Methamphetamine-associated cognitive decline is attenuated by neutralizing IL-1 signaling. *Brain Behav Immun*. 2019; 80:247-54. <https://doi.org/10.1016/j.bbi.2019.03.016>
29. Speck AE, Tromm CB, Pozzi BG, Paganini CS, Tuon T, Silveira PC and et al. The dose-dependent antioxidant effects of physical exercise in the hippocampus of mice. *Neurochem Res*. 2014; 39:1496-501. <https://link.springer.com/article/10.1007/s11064-014-1339-6>
30. Toborek M, Seelbach MJ, Rashid CS, András IE, Chen L, Park M and et al. Voluntary exercise protects against methamphetamine-induced oxidative stress in brain microvasculature and disruption of the blood-brain barrier. *Mol Neurodegener*. 2013; 8:1-1. <https://link.springer.com/article/10.1186/1750-1326-8-22>
31. Coppola M, Tirrito E, Karevski D, Collura M. Growth of entanglement entropy under local projective measurements. *Phys Rev*. 2022; 105(9):094303. <https://journals.aps.org/prb/abstract/10.1103/PhysRevB.105.094303>
32. Bogenschutz MP, Forcehimes AA, Pommy JA, Wilcox CE, Barbosa PC, Strassman RJ. Psilocybin-assisted treatment for alcohol dependence: a proof-of-concept study. *J Psychopharmacol*. 2015; 29(3):289-99. <https://doi.org/10.1177/0269881114565144>
33. Du Jardin KG, Liebenberg N, Cajina M, Müller HK, Elfving B, Sanchez C and et al. S-ketamine mediates its acute and sustained antidepressant-like activity through a 5-HT1B receptor dependent mechanism in a genetic rat model of depression. *Front Pharmacol*. 2018; 8:978. <https://doi.org/10.3389/fphar.2017.00978>
34. Daniel J, Haberman M. Clinical potential of psilocybin as a treatment for mental health conditions. *Ment Health Clin*. 2017; 7(1):24-8. <https://doi.org/10.9740/mhc.2017.01.024>
35. Kraehenmann R, Preller KH, Scheidegger M, Pokorny T, Bosch OG, Seifritz E and et al. Psilocybin-induced decrease in amygdala reactivity correlates with enhanced positive mood in healthy volunteers. *Biol Psychiatry*. 2015; 78(8):572-81. <https://doi.org/10.1016/j.biopsych.2014.04.010>