Ilam University of Medical Sciences
Journal of Basic Research in Medical Sciences
Online ISSN: 2383-0972
Print ISSN: 2383-0506
Homepage: https://jbrms.medilam.ac.ir

Investigating the protective effect of *Aloe vera* gel on the endocrine tissue of the pituitary gland in rats receiving lead acetate

Taher Jamshidzadeh[1], Ali Mohammad Bahrami[1]✉, Shahnaz Yousefizadeh[2]✉, Nematollah Shakrami[1]

[1] Department of Histology, Faculty of Para-veterinary, Ilam University, Ilam, Iran
[2] Department of Laboratory and Clinical Sciences, Faculty of Para-veterinary, Ilam University, Ilam, Iran

Article Info

Article type:
Research Article

Article history:
Received: 3 Jun. 2023
Revised: 27 Jun. 2023
Accepted: 18 Sep. 2023
Published online: 24 Oct. 2023

✉**Correspondence to:**
Ali Mohammad Bahrami, Department of Histology and Microbiology, Faculty of Para-veterinary, Ilam University, Ilam, Iran.
Email: am.bahrami@ilam.ac.ir
Shahnaz Yousefizadeh, Department of Laboratory and Clinical Sciences, Faculty of Para-veterinary, Ilam University, Ilam, Iran.
Email: sh.yousefizadeh@ilam.ac.ir
Postal Code: 6939177111
Tel: +98 8432227029
Fax: +98 8432227029

ABSTRACT

Introduction: Lead is one of the most important heavy metals polluting the environment and it enters the body of humans and animals through digestion and breathing and has toxic effects on different body tissues. In the present study, the protective properties of *Aloe vera* plant gel in the pituitary tissue following lead acetate poisoning were investigated.

Materials and Methods: In this experimental study, 32 male Wistar rats were randomly divided into 4 equal groups including; The control group: (normal saline, IP), lead acetate group: (20 mg/kg/day, IP), lead acetate-*Aloe vera* group: lead acetate (20 mg/kg/day, IP) + *Aloe vera* gel (400 mg/kg/day, oral) and *Aloe vera* group: *Aloe vera* gel (400 mg/kg/day, oral). After six weeks, the rats were euthanized and the pituitary glands from each animal were dissected. For the microscopic examination of tissue sections, hematoxylin-eosin staining was performed.

Results: The results of the present study showed that treatment with lead acetate caused changes such as weight loss ($P < 0.05$), atrophy, and hyperemia, as well as tissue changes, including a general decrease in the number of cells in the pituitary gland ($P < 0.05$). Administration of *Aloe vera* gel (400 mg/kg) improved all the microscopic complications and disorders and macroscopic changes caused by lead acetate in the pituitary tissue.

Conclusion: It can be concluded that *Aloe vera* played an ameliorative role in the lead acetate-mediated pituitary injury in rats.

Keywords: *Aloe vera*, Lead acetate, Pituitary, Rat

How to cite this article: Jamshidzadeh T, Bahrami AM, Yousefizadeh Sh, Shakrami N. Investigating the protective effect of *Aloe vera* gel on the endocrine tissue of the pituitary gland in rats receiving lead acetate. J Bas Res Med Sci. 2023; 10(2):33-40.

© The Author(s). Publisher: Ilam University of Medical Sciences

Introduction

As a heavy and toxic metal, lead is considered the biggest polluter in the world (1). Lead can be absorbed by the body through breathing, eating, and skin and lead to dysfunction of various organs (2). Lead poisoning, even in small amounts, can affect biochemical structures and physiological processes and lead to diseases such as cancer (3). Lead causes

[Downloaded from jbrms.medilam.ac.ir on 2026-11-24]

DNA damage by peroxidation of membrane lipids and also enters the nervous system by increasing the permeability of the blood-brain barrier and leads to the induction of oxidative stress and apoptosis (4, 5, 6). Studies show that after entering the body, lead causes a decrease in the level of antioxidant enzymes, as well as oxidative damage and dysfunction in various body systems, including the central and peripheral nervous system, endocrine system, reproductive system, and other body systems (4). The results of research showed that treatment with lead acetate can cause a significant reduction in the weight of the cerebellum and brain and disrupt the functioning of the nervous system (7). In another study, researchers found that exposure to lead acetate causes nerve tissue damage, myelin sheath loss, collagen scar tissue formation, and nerve cell atrophy in mice (8). The use of medicinal plants has become popular due to their cheapness, antioxidant and protective properties, and fewer side effects (9). One of these medicinal plants is the yellow patience plant or *Aloe vera* it is full of different antioxidants and has the ability to neutralize free radicals in the body (10). Also, research shows that *Aloe vera* leaf extract can reduce the level of some liver enzymes, blood fat, and some other blood elements (11, 12). The main side effect of the topical use of *Aloe vera* gel is allergic contact dermatitis, and if used properly, its oral consumption is very harmless (7). The present study was conducted with the aim of investigating the protective role of *Aloe vera* plant gel on the damage caused by receiving lead acetate in the pituitary tissue of rats.

Materials and Methods

In this experimental study, 32 male Wistar adult (230 ± 4, n=32) rats were provided from the laboratory animal center of the Para-veterinary College of Ilam University. In order to adapt to the environmental conditions, the animals were kept for one week and then randomly divided into four groups; control group: (normal saline, IP) (n=8), lead acetate group: (20 mg/kg/day, IP) (n=8), the lead acetate-*Aloe vera* group: lead acetate (20 mg/kg/day, IP) + *Aloe vera* gel (400 mg/kg/day, oral) (n=8) and *Aloe vera* group: *Aloe vera* gel (400 mg/kg/day, oral) (n=8). During the study, all the rats were kept at a temperature of 25±2 ºC and under a 12 h light-dark cycle (lights on at 07:00 h). They had free access to tap water and food *ad libitum*. The dose used in this study for lead acetate and the effective dose of *Aloe vera* plant gel were selected based on previous studies (13, 14). On day 42, the weight of the animals was recorded with a digital scale (AND model Fx3001, Japan) and then, following the ethical principles of working with laboratory animals (Ethics ID: IR.ILAM.REC.1402.008), all animals were anesthetized with chloroform (Rotex Media, Germany) and then using a razor and Using surgical scissors, the scalp was first removed, and then by cutting the parietal bone and removing the skull roof and removing the brain completely, the pituitary gland sample was taken from inside the Turkish saddle with the tip of forceps and placed in a 10% buffered formalin solution (tar). Shimi Tehiz, Iran) was transferred. Also, after 24 hours, the formalin solution was changed to make a proper confirmation in order to prevent autolysis and cell corruption. After complete fixation in formalin solution, the pituitary tissue samples were molded with paraffin solution (Tarran Shimi Tehiz, Iran) and using a rotary microtome (Pound Ab, Iran) 5-micron thick sections were prepared from them and using the method Hematoxylin-eosin (H&E) (Merck, Germany) were stained (15). Finally, using an optical microscope (cxT, Olympus, Germany), the tissue and cellular changes and the endocrine parts of the pituitary gland (posterior and middle parts) of the tissue sections prepared from all groups in terms of quality (histology) such as the state

[Downloaded from jbrms.medilam.ac.ir on 2026-11-24]

of makeup and The density of cells and also quantitatively (histometric) including the number of types of cells (acidophile, basophil and chromophobe) were counted and the changes made in the groups treated with lead acetate compared to the control group and also the changes in the lead acetate-*Aloe vera* group compared to the group Lead acetate was compared.

Statistical Analysis

SPSS version 16 software was used for statistical analysis of the data obtained and for comparison between the different groups studied. The data were then expressed as mean ± standard deviation and the one-way ANOVA and LSD (Least Significant Difference) post hoc test were used to compare the groups. In all cases, a value of $P < 0.05$ was used as the criterion for a minimum statistically significant difference.

Results

Due to the same conditions of the animals at the beginning of the experiment, the result of measuring the weight of the animals at the beginning of the work did not show a significant difference (Table 1). But at the end of the experiment, the measurement of the weight of the animals showed that in the lead acetate group, the weight of the animals had decreased significantly compared to the control group ($P < 0.05$). In the lead acetate-*Aloe vera* group, the treatment with *Aloe vera* increased the weight of these animals compared to the lead acetate group ($P < 0.05$). The intake of *Aloe vera* in the healthy rats of the *Aloe vera* group did not make a significant difference compared to the control group. Also, the comparison of the weight of the pituitary gland in different groups revealed that the weight of the pituitary gland in the lead acetate group showed a significant decrease compared to the control group ($P < 0.05$). In the lead acetate-*Aloe vera* group, there was a significant increase in the weight of the pituitary gland compared to the *Aloe vera* group ($P < 0.05$). There was no significant difference in the weight of the pituitary gland in the *Aloe vera* group compared to the control group (Table 1). In the microscopic observations of the sections prepared from the pituitary gland part of the control group rats, three parts of the pituitary gland (posterior region, middle region and tubular region) can be distinguished (Figure 1).

Table 1. The effects of lead acetate on the body weight gain and pituitary gland weight.

Treatment groups	Body weight (gr)		Pituitary gland weight (gr)
	Start the test	End of experiment	
Control	184.25 ± 3.46 [b]	207.85 ± 6.22 [a]	0.044 ± 0.022[a]
Lead acetate	190.43 ± 2.12 [a]	176.53 ± 4.84 [b]	0.014 ± 0.011 [b]
Lead acetate - *Aloe vera*	188.03 ± 3.25 [b]	195.47 ± 7.61 [a]	0.038 ± 0.02 [a]
Aloe vera	188.49 ± 2.225 [b]	203.11 ± 4.40 [a]	0.041 ± 0.019 [a]

Data are shown as mean ± SD. a, b, c: Dissimilar characters in each column indicate statistically significant differences between t groups ($P < 0.05$).

In the comparison of the histological structure of the pituitary gland in the lead acetate group compared to the control group, the most important change that could be seen was the lower cell density in all types of cells (acidophilic, basophilic and chromophobe) in the posterior and middle pituitary.

Also, disruption of the order and arrangement of cells in the tissue structure of the pituitary gland, heterochromatinized, and the disappearance of the nucleus in many cells and cytoplasmic vacuolation, which lead to the creation of empty tissue spaces in this group compared to the control group, which is a sign of cell destruction and necrosis was visible.

[Downloaded from jbrms.medilam.ac.ir on 2026-11-24]

The histological observations of the pituitary gland showed that receiving Aloe vera plant gel in the rats of the lead acetate-Aloe vera group caused a reduction in the density and cell disorder created in the lead acetate group, which was clearly improved and close to normal conditions (Figure 1). In the histological examination of the pituitary gland in the rats of the *Aloe vera* group, no significant structural changes were observed compared to the control group (Figure 1).

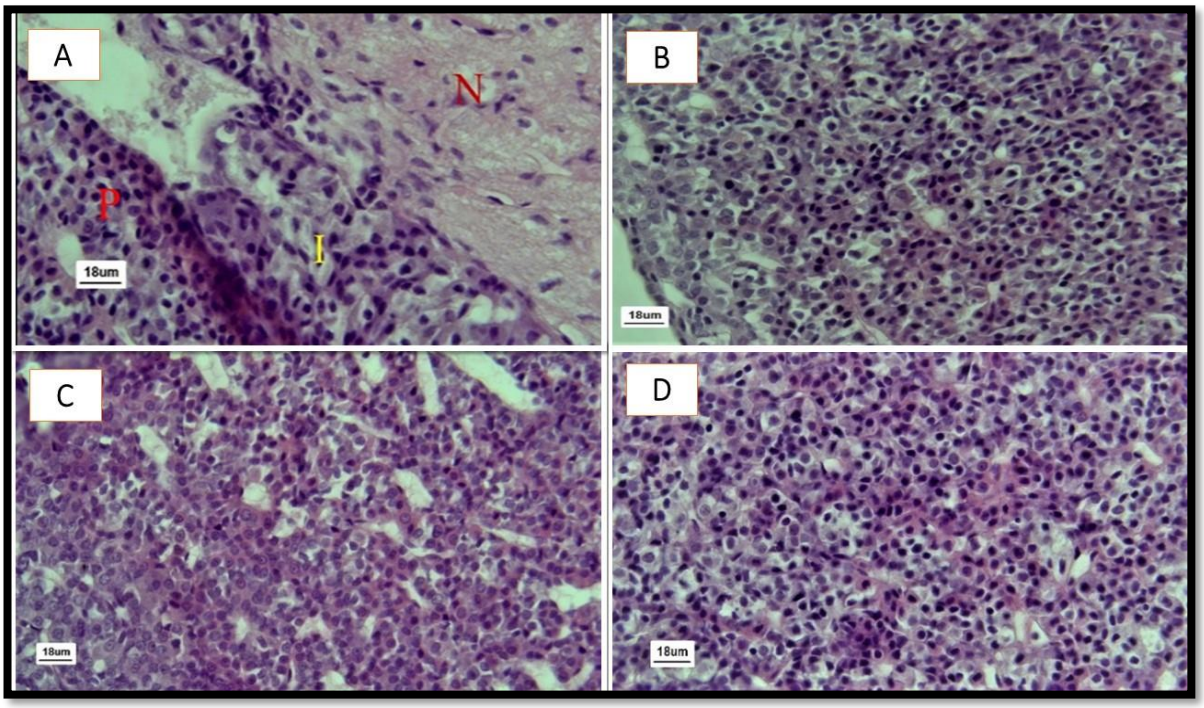

Figure 1. View and compare the tissue structure of the three main parts of the pituitary gland in different **groups. A: control group.** Normal tissue structure and cell density are observed. **B: lead acetate group.** Disruption of the cellular arrangement of the pituitary gland tissue and a general decrease in the number of cells, heterochromatinization and fading of the nucleus, and cytoplasmic vacuolation. **C: lead acetate-*Aloe vera* group.** Improving the state of cellular and tissue order and increasing the total number of cells. **D: *Aloe vera* group.** Structurally and cellularly, it is not significantly different from the control group. Posterior section (P), middle section (I), and neural section (N) (hematoxylin-eosin staining. 40x magnification).

Histometric Results

In order to investigate the changes and structural differences created in the study groups and to quantify them, the difference in cell population was evaluated, and the number of acidophilic, basophil and chromophobe cells between different groups was compared. The results of counting acidophilic cells in different areas of the pituitary tissue showed that the average number of these cells in the lead acetate group decreased significantly compared to the control group ($P < 0.05$). Our findings showed that the average number of acidophilic cells after receiving *Aloe vera* plant gel in the lead acetate group-*Aloe vera* compared to the lead acetate group, increased significantly ($P < 0.05$). The average number of acidophilic cells in the *Aloe vera* group compared to the control group had a significant difference (Table 2). Investigations showed that after receiving lead acetate, the average number of basophil cells decreased significantly ($P < 0.05$).

owever, the administration of *Aloe vera* plant gel in the lead acetate-*Aloe vera* group caused a significant increase in the average number of basophil cells compared to the lead acetate group ($P < 0.05$). Comparison of the average number of basophilic cells in

[Downloaded from jbrms.medilam.ac.ir on 2026-11-24]

the *Aloe vera* group did not show a significant difference (Table 2).

The results of counting chromophobe cells in different studied groups did not show any significant difference across groups (Table 2). Microscopic evaluations of various areas of the pituitary tissue showed that treatment with lead acetate resulted in a decrease in cell density and disruption of the arrangement of cells in different areas of the pituitary gland and receiving the gel of the *Aloe vera* plant improved the density and order of cells (Figure 2).

Table 2. The effects of lead acetate on the average number of pituitary gland cells.

	Average number of acidophilic cells	Average number of Basophil cells	Average number of chromophobe cells
Control	9.12 ± 0.075 [a]	11.93 ± 0.69[a]	7.65 ± 0.13 [a]
Lead acetate	5.31 ± 0.63 [b]	7.24 ± 0.13 [b]	6.94 ± 0.22[b]
Lead acetate-*Aloe vera*	7.58 ± 0.22 [a]	1.51 ± 0.24[a]	7.21 ± 0.76[a]
Aloe vera	8.22 ± 0.22 [a]	9.94 ± 0.33[a]	8.01 ± 0.12 [a]

Data are shown as mean ± SD. a, b, c: Dissimilar characters in each column indicate statistically significant differences between t groups (P < 0.05).

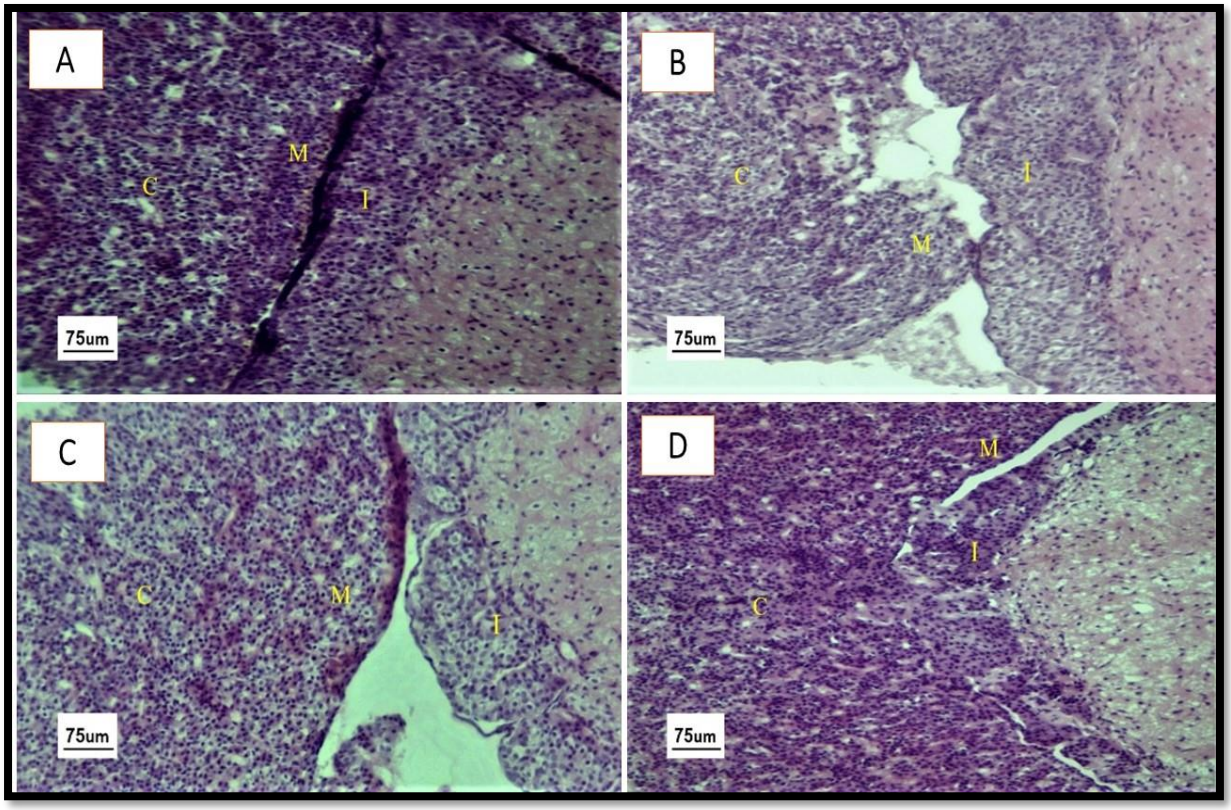

Figure 2. A: control group. Density and dispersion of pituitary cells. Normal arrangement and accumulation of cells of the posterior pituitary. **B: lead acetate group.** Disruption of the arrangement and decrease in the accumulation and density of cells of the posterior pituitary. **C: lead acetate- *Aloe vera* group.** Relative improvement of the state of cell order and increase in the density of cells of the posterior pituitary. **D: *Aloe vera* group.** The condition of the tissue and cellular structure in the posterior pituitary is almost the same as in the control group. The middle region of the Glandularpituitary (I), marginal region of the posterior pituitary (M), and central region of the posterior pituitary (C). (hematoxylin-eosin staining, 40x magnification).

Discussion

Lead is one of the main polluters of the environment, which nowadays has become one of the most important harmful factors

[Downloaded from jbrms.medilam.ac.ir on 2026-11-24]

of human health in industrialized societies. The purpose of this study was to investigate the medicinal and protective properties of *Aloe vera* plant gel on the adverse effects caused by the administration of lead acetate on the pituitary gland. In relation to the effect of lead acetate on the pituitary gland, not many studies have been conducted in the past, but regarding its effect on body weight and the volume and size of different organs in previous studies, different results have been reported. In the study of the effect of lead acetate on the kidneys of rats, observed that although the animals had a slight weight loss, the organs of all the studied animals had an increase in volume and measure (16).

The harmful effects of lead acetate on the nervous tissues have been proven in various studies. For example, it was reported that the administration of lead acetate (20 mg/kg) for eight weeks caused a decrease in body and brain weight (14). There is evidence that lead causes behavioral and chemical reactions in people (17). There are also many reports that this toxic substance causes structural changes and dysfunction in the body's endocrine glands and hormonal settings (18). It has been proved that the mechanism of the toxic effects of lead acetate on the human body is through the production of free radicals and as a result, the increase of lipid peroxidation and the creation of oxidative stress, which causes disturbances in the function of body systems (19, 13).

The results of this study showed that the rats receiving lead acetate had severe weight loss, atrophy, and a decrease in the density and cell order of the pituitary gland compared to the control group. The presence of such evidence in the appearance of the pituitary gland in the rats of the lead acetate group probably indicates a severe decrease in the activity and function of this gland under the influence of lead acetate. Also, the results of the present study showed that the oral intake of *Aloe vera* plant gel, due to its protective properties, can reduce the damage caused by the administration of lead acetate in the pituitary gland and improve its cellular structure and order.

Among the strong antioxidant compounds produced by plants as active secondary metabolites, phenolic acids have always been of interest. The antioxidant properties of these compounds are mainly due to their ability as a reducing agent, hydrogen donor, and inhibitor of oxygen free radicals, which enables them to delay the oxidation of lipids and soluble compounds in them (20). Also, salicylic acid and magnesium lactate present in *Aloe vera* plant gel inhibit prostaglandin and histidine decarboxylase, and as a result, inhibit the conversion of histidine to histamine in mast cells and reduce inflammation in the tissue. The anti-inflammatory properties of *Aloe vera* are related to the presence of these compounds (21).

In this study, it seems that lead acetate causes its destructive effects through the production of free radicals and inflammatory mediators and the stimulation of factors that cause apoptosis and necrosis. It destroys cellular order and arrangement as well as causes cell damage. on the other hand, *Aloe vera* plant gel has reduced tissue damage due to its properties of strong antioxidants and inhibition of free radicals, as well as the presence of anti-inflammatory compounds. On the other hand, the presence of other compounds with healing properties in the gel of this plant caused cellular and tissue regeneration in the structure of the pituitary gland, which results are in agreement with other studies (22).

Also, lead inhibits the antioxidant defense by reducing the level of enzymes related to the cellular antioxidant system, increases the accumulation of free radicals, and damages cells (1). It has been shown that the consumption of plant flavonoids such as *Aloe vera* can protect against tissue damage in conditions of oxidative stress. Also, *Aloe vera* extract and gel contain phenolic

[Downloaded from jbrms.medilam.ac.ir on 2026-11-24]

compounds, and many antioxidant and protective properties are associated with these substances (23). The results of the study of the effect of the *Aloe vera* plant on nerve tissue repair showed that the aqueous-alcoholic extract of *Aloe vera* leads to the reduction of damage to nerve fibers in diabetic conditions (24).

One of the limitations of this research was the lack of access to diagnostic kits for hormones secreted by the pituitary gland, so it is suggested to evaluate the secretory function of the pituitary gland in the condition of lead poisoning in future research.

Conclusion

The results of this study showed that lead acetate, as a toxic substance, causes destructive changes, including weight loss, pituitary gland destruction, and disruption of the order and arrangement of all types of tissue cells. Oral consumption of *Aloe vera* gel prevents the harmful effects of lead acetate on the pituitary gland.

Acknowledgments

The current research is derived from the master's thesis in the field of histology and was carried out in the para-veterinary faculty of Ilam University.

References

1. Pande M, Flora SJ. Lead induced oxidative damage and its response to combined administration of alpha lipoic acid and succimers in rats. Toxicol. 2002; 177(2-3): 187-96. doi: 10.1016/S0300 483X(02)00223-8.
2. Moore MR, Meredith PA. Watson, WS. Summer, DJ. Taylor, MK. Goldberg A. The percutaneous absorption of lead-203 in human's cosmetic preparations containing lead acetate, as assessed by whol-body counting other techniques. Food Cosmet Toxicol. 1980; 18(40): 399-405.doi: 10.1016/0015-6264(80)90197-2.
3. Chen X, Yang Q, Smith G, KrewskiD, Walker M, Wen S. Environmental lead level and pregnancy-induced hypertension. Environ Res. 2006; 100(3): 424-43. doi: 10.1016/j.envres.2005.07.006.
4. Jaako-Movits K, Zharkovsky T, Romantchik O, et al. Developmental lead exposure impairs contextual fear conditioning and reduces adult hippocampal neurogenesis in the rat brain. Int J Dev Neurosci. 2005; 23(7):627-35. doi: 10.1016/j.ijdevneu.2005.07.005.
5. Lawton LJ, Donaldson WA. Lead-indused tissue fatty acid alteration and lipid peroxidation. Biol Trace Elem Res. 1991; 28(2): 83-97. doi: 10.1007/BF02863075.
6. Soltaninejad K, Kebriaeezadeh A, Minaiee B, Ostad SN, Hosseini R, Azizi E, Abdollahi M. Biochemical and ultrastructural evidences for toxicity of lead through free radicals in rat brain. Hum Exp Toxicol. 2003; 22(8):417-23. doi: 10.1191/0960327103ht385oa.
7. Sidhu P, Nehru B. Lead Intoxication: Histological and Oxidative Damage in Rat Cerebrum and Cerebellum. J Trace Elem Exp Med. 2004; 17(1):45-53. doi: 10.1002/jtra.10052.
8. Shelton RM. *Aloe vera*. Int J dermatol. 1991; 30(10):679-83. doi: 10.1111/j.1365-4362.1991.tb02607.x.
9. Katzaung BG. Basic & Clinical Pharmacology. 10th ed. USA, McGraw-Hill Companies. 2007; 478-88.
10. Bassetti AL, Sala ST. The grate Aloe book.1st ed. Zuccari Editions. 2005; 47-51.
11. Davis RH. Biological activity of *Aloe vera*. SÖFW J. 1993 (119): 646-9.

[Downloaded from jbrms.medilam.ac.ir on 2026-11-24]

12. Perez YY, Jimenez-Ferrer E, Zamilpa A, Hernandez-Valencia M, Alarcon-Aquilar FJ, Tortoriello J, et al. Effect of a polyphenol-rich extract from *Aloe vera* gel on experimentally induced insulin resistannce in mice. Am J Chin Med. 2007; 35(6): 1037-46. doi: 10.1142/S0192415X07005491.
13. Zadjali S, Nemmar A, Fahim MA, Azimullah SH, et al. Lead exposure causes thyroid abnormalities in diabetic rats. Int J Clin Exp Med. 2015; 8(5): 7160–7.
14. Hosseinzadeh S, Dabidi-Roshan V, Mahjoub S, Taghipour-Darzi M. The interactive effect of lead acetate and endurance training on brain-derived neurotrophic factor and malondialdehyde levels in rat cerebral cortex. J Babol Med Sci. 2019; 14(2): 7-15.
15. Esua MF, Rauwald JW. Novel bioactive maloylglucans from *Aloe vera* gel: isolation, structure elucidation and in vitro bioassays. Carbohydrate Res. 2006; 341(4):355-64. doi: 10.1016/j.carres.2005.11.022.
16. Heidari Z, Sagheb H, Dezfoulian A, Barbarestani M, Noori H. A stereological analysis of renal glomerulifollowing chronic lead intoxication in rat during acontinuous period of 8 weeks. Acta Med Iran. 2002; 40(2): 73-78.
17. Nouri S, Sharif MR. Hemostatic effect of aluminum chloride in liverbleeding: an animal model study. Tehran Univ Med J. 2014;72(7):435-42.
18. Ibrahim NM, Eweis EA, El-Beltagi H, Abdel-Mobdy YE. Effect of lead acetate toxicity on experimental male albino rat. Asian Pac J Trop Biomed. 2012; 2(1): 41–46.doi: 10.1016/S2221-1691(11)60187-1.
19. Yin ST, Tang ML, Su L, Chen L, Hu P, Wang HL, et al. Effects of Epigallocatechin-3-gallate on lead-induced oxidative damage. Toxicology. 2008; 249(1): 45-54. doi: 10.1016/j.tox.2008.04.006.
20. Pedriell P,Pedulli GF, Skibsted LH. Antioxidant Mechanism of Flavonoids. Solvent Effect on Rate Constant for Chain-Breaking Reaction of Quercetin and Epicatechin in Autoxidation of Methyl Linoleate. J Agric Food Chem. 2001; 49(6): 3034-40. doi: 10.1021/jf010017g.
21. Subramanyan S, Sathish Kumar D, Arulselvan P. Wound healing potential of *Aloe vera* leaf gel studied in experimental rabbit. Asian J Biochem. 2006; 1(2):178-85. doi: 10.3923/ajb.2006.178.185.
22. Noor A., Gunasekaran S., SoosaiManickam A. and Vijayalakshmi M.A. Antidiabetic activity of *Aloe vera* and histology of organs in streptozotocin induced diabetic rats. Curr Sci. 2008; 94(8): 1070-76.
23. Bahrami-Tepebor M, Mazaheri Y, Khaksari-Mahabadi M, Fatemi-Tabatabai SR, Tabandeh MR. The *Aloe vera* gel improves structural disorders in the brain of streptozotocin-induced diabetic male rats. J Isfahan Med Sch. 2017; 35(422): 235-42.
24. Habibian M, DebidiRoshan WA, Mousavi SJ, Mahmoudi SA. The protective effect of aerobic exercise on oxidative stress caused by lead in rat cerebellum. J Gorgan Uni Med Sci. 2013; 15(3): 39-43.

[Downloaded from jbrms.medilam.ac.ir on 2026-11-24]