

## Molecular identification of *Dicrocoelium dendriticum* using 28s rDNA genomic marker and its histopathologic features in domestic animals in western Iran

Mohammad Hossein Ebrahim Pour<sup>1</sup>, Bahar Shemshadi<sup>1\*</sup>, Ali Mohammad Bahrami<sup>2</sup>, Salome Shirali<sup>3</sup>

1. Department of Pathobiology, Science and Research Branch, Islamic Azad University, Tehran, Iran
2. Department of Pathobiology, Para Veterinary Faculty, Ilam University, Ilam, Iran
3. Department of Biotechnology, Ahvaz Branch, Islamic Azad University, Ahvaz, Iran

\*Corresponding author: Tel: +98 9125082497 Fax: +98 2144868613

Address: Department of Pathobiology, Science and Research Branch, Islamic Azad University, Tehran, Iran

E-mail: bshemshadi@yahoo.com

Received; 2/04/2020 Revised; 1/07/2020 Accepted; 27/08/2020

### Abstract

**Introduction:** Dicrocoeliasis is a common disease of bile ducts and gallbladder of domestic and wild ruminants. This disease is caused by different species of *dicrocoelium* including *Dicrocoelium dendriticum*. The aim of this study was to identify pathological damages and molecular features associated with this parasite in ruminants.

**Materials and Methods:** In this cross-sectional study, 180 fresh adult *D. dendriticum* worms were collected from 45 infected livers of slaughtered cattle, sheep, and goats in three western provinces of Iran. After histopathological examination, a 963 bp fragment (28S rRNA gene) was amplified using Polymerase Chain Reaction (PCR). The amplified fragment was digested by Tru11 restriction enzyme to evaluate through Restriction Fragment Length Polymorphism (RFLP) method.

**Results:** Based on histological examination, hyperplasia of mucosal glands and swelling of bile ducts of infected livers were observed. In all studied samples, a 963-bp fragment was produced by PCR. Based on PCR-RFLP, the PCR products were digested by Tru11 restriction enzyme producing four fragments (116 bp, 145 bp, 293 bp, and 409 bp) all of which were related to *D. dendriticum*. Sequencing of the obtained 28S rDNA fragments showed that all of them were completely similar, and comparing them with the Gene Bank sequences showed 97% to 100% similarity between homogeneous fragments. The obtained sequences were registered in the Gene Bank with the accession numbers of MT539114, MT539115, and MT539116.

**Conclusion:** According to the present study, *D. dendriticum* is the predominant parasite infecting ruminants in west of Iran.

**Keywords:** *Dicrocoelium dendriticum*, Pathology, 28s rDNA, PCR-RFLP, Sequencing

### Introduction

Proteins are among main groups of humans' dietary requirements. In the recent decades, the need for better quality and healthier protein resources has been more than ever due to growing populations across the world. Meat and other animal protein products have a special place in humans' nutrition. The

livestock population in Iran, which is estimated to consist of 80 million sheep and goats and 8 million cattle, is considered as an essential component of food security (1). Due to the lack of accurate monitoring systems, it is not possible to accurately estimate the global economic losses caused by food-borne parasitic diseases. However, annual estimates reflect a high economic burden for covering

Copyright © 2020 Journal of Basic Research in Medical Science. This is an open access article distributed under the terms of the Creative Commons Attribution 4.0 International License (<https://creativecommons.org/licenses/by-nc/4.0/>), which permits copy and redistribute the material, in any medium or format, provided that the original work is properly cited.

the costs of treatment and prevention of these diseases in the livestock and human sectors. Furthermore, additional financial losses are inevitable owing to mortality, confiscation of contaminated corpses, and finally the reduced supply of livestock products (2).

Dicrocoeliasis is a common disease of bile ducts and gallbladder of domestic and wild ruminants, which may be also observed in rabbits, pigs, horses, and humans as well. The disease has a global dissemination and is caused by different species of *Dicrocoelium* (3-6). Until now, 5 species of *Dicrocoelium* have been identified as: *D. dendriticum* (across Europe, Africa, and America), *D. Haspes* and *D. Orientalis* (in Africa), *D. Superci* (in Europe), and *D. Chinensis* (in Asia) (7, 8). Among all these species, *D. dendriticum* is the most important in medicine, veterinary sciences, and economic industries (9-11).

The prevalence of human infection with *D. dendriticum* has increased in recent years, rendering the hepatic trematode as one of the most important threats towards human health (12). *D. dendriticum*, with its amazing life cycle, seriously endangers its hosts' health by causing severe liver infections which require an exaggerated use of anthelmintic drugs and are associated with high mortality, a fall in the supply of livestock products, and significant damages to the economy and human health (13-15). In a systematic review and meta-analysis study in Iran, the relative prevalence of the infection in slaughtered sheep, goats, and cows have been reported as 3.1%, 1.3%, and 0.5%, respectively (10). The economic value of the extinct livers infected with this worm in slaughterhouses of Iran has been estimated over 8000000 \$ (16).

Human is an occasional host of *D. dendriticum*, and human infections have been reported from various regions of Iran (e.g. Isfahan, Urmia, Gonbad-e-Kavous, and Caspian coastal areas) (17-19). Several studies have been performed in Iran to

identify *D. dendriticum* genotypes, but no parallel investigations have yet been conducted on the molecular and histopathological features of this infection in western provinces of the country (Ilam, Kermanshah, and Kurdistan) in which the main occupation of nomads and rural population is livestock and animal husbandry. The present study was performed to accurately identify the ancestral roots of this infection based on 28s rDNA genomic marker and investigate the pathological injuries caused by the infection in these provinces.

## Materials and Methods

### Sample Collection

This cross-sectional study was conducted on 45 livers (15 cattle, 15 sheep, and 15 goats) infected with *Dicrocoelium*. The livers were collected from the industrial slaughterhouses of Ilam, Kermanshah, and Kurdistan provinces (15 livers from each province). The samples were collected in different seasons between 2018 and 2019. Adult worms were immersed in 80% alcohol and stored in freezer (-20 °C) until DNA extraction. Liver tissues were kept in 10% formalin until histopathological studies.

### Histopathological Study

First, the infected livers were macroscopically evaluated according to their color, size, and consistency. Then paraffin tissue blocks were prepared, and thin tissue sections were obtained using a microtome device. The tissue sections were finally stained with hematoxylin and eosin (H&E) and examined by light microscopy.

### DNA Extraction

Adult parasites from four randomly selected hosts were obtained and washed with PBS (8000 rpm for three times). Genomic DNA of

all *Dicrocoelium spp.* was extracted using a commercial DNA extraction Kit purchased from Molecular Biological System Transfer institute (MBST, Iran) according to the manufacturer's instructions. The extracted DNA was evaluated by agarose gel electrophoresis and nanodrop methods. The samples were kept at -20 °C until use.

### PCR Reaction

A fragment (approximately 963 bp) of the 28S rDNA marker was amplified using the primers manufactured by Sina Gene Technologies Co. (Iran) (Table 1).

**Table 1.** Specific primers used to amplify the 28S rDNA region of *Dicrocoelium spp.*

Primer	Primer sequence	Amplicon
Forward	TGGCCACTTGGTCATT A	963bp
Reverse	ACCTCAGTCTGGACAAGCCA	

PCR amplification was applied in a final volume of 100 µl including 10 µl of 10x buffer, 2 µl of the parasite DNA, 2 µl dNTP, 3 µl MgCl<sub>2</sub>, 0.5 µl Taq DNA polymerase, 2 µl forward primer, 2 µl reverse primer and 78.5 µl nuclease-free water. In all PCR reactions, a tube without DNA was used as a negative control. PCR reaction was conducted using gradient "My Cycler" device (Optimax Labnet, USA). Thermal protocol included an initial incubation at 95 °C for 5 minutes, and then 30 cycles of denaturation at 94°C for 50 seconds, annealing at 55 °C for 50 seconds, and extension at 72 °C for 1 minute. Finally, the reaction continued for 5 minutes at 72 °C (23). PCR products (4 µl) along with 100 bp DNA marker and the negative control sample were electrophoresed on 1.2% (w/v) agarose gel at 110 V for 75 minutes. Then the bands were observed and analyzed using a transilluminator (23).

### RFLP-PCR

To digest PCR products, the TruI restriction enzyme (Termo scientific, Lithuania), which detects TT/AA sequences, was used. This enzyme specifically differentiates *D. dendriticum* from its similar counterpart (i.e. *D. haspes*); however, it lacks a cleavage site on *D. chinensis*. For performing the RFLP reaction, a mixture was prepared containing 2 µl of the PCR product, 1 µl buffer, 0.5 µl TruI restriction enzyme, and 11.5 µl double-distilled water (the net volume of 15 µl). The mixture was incubated at 65 °C for one hour (24). Then 4 µl of the PCR-RFLP product was electrophoresed on 1.2% agarose gel next to a 100-bp DNA marker (70 V for 20 minutes). The bands were visualized in a transilluminator after ethidium bromide staining (9, 24).

### Sequencing and Preparing the Phylogenetic Tree

In order to obtain the sequences of the amplified 28S rDNA genes of *dicrocoelium*, a total of nine PCR products (one product from each host in each province) were sent for sequencing (Takapo Zist, Iran). The sequences were then matched against the registered items in the Gene Bank using the Basic Local Alignment Search Tool (BLAST) and the Clastalw v.2 software. The phylogenetic tree was plotted after multiple aligning of the obtained sequences with those of the Plajurcid order registered in the Gene Bank using the MEGA6 software and the Neighbor Joining algorithm with 2000 replications (9, 25).

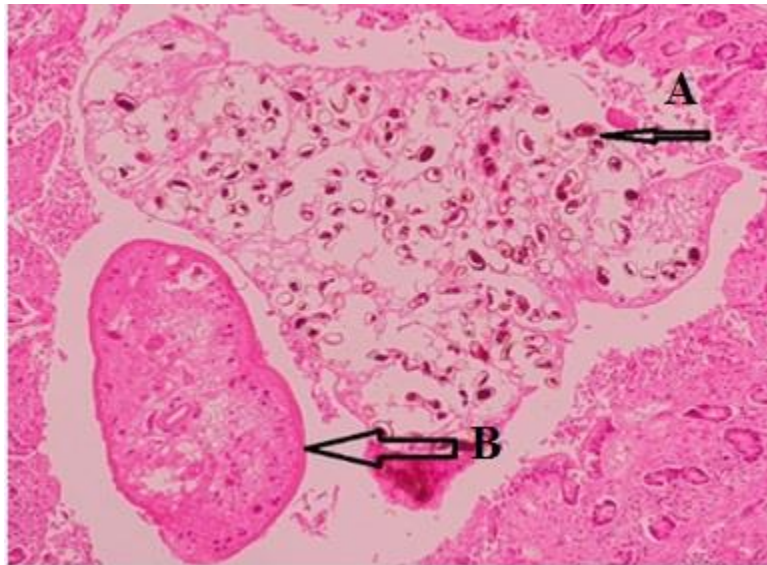
## Results

### Histopathological Analysis

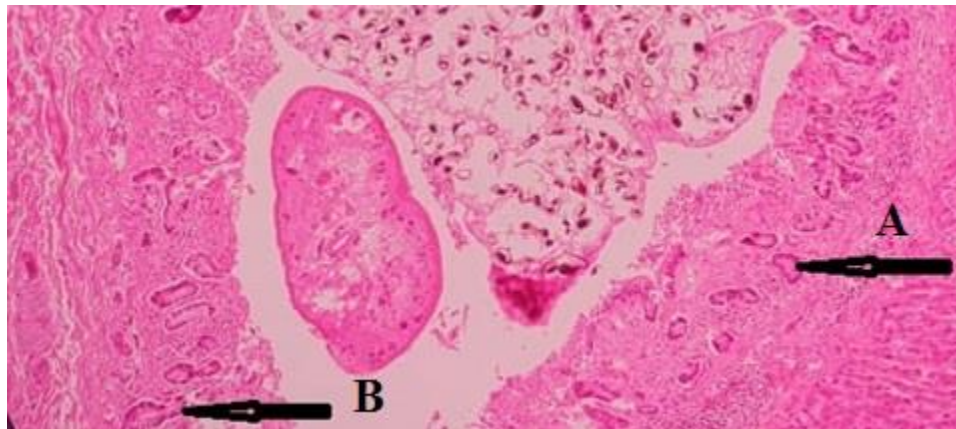
Macroscopic examination of the infected livers revealed wrinkled and dark-blue (sometimes red) hematoma and hyaline, needle-shape spots, and the complete lack of the sharpness of liver margins and tips. In microscopic pathological examination, the

parasite eggs were clearly visible within bile ducts (Figure 1). The swelling and dilation of bile ducts due to the presence of adult worms were observed (Figure 2). Damage to the epithelial tissue around the bile ducts, villous atrophy, hyperplasia of bile duct mucosal

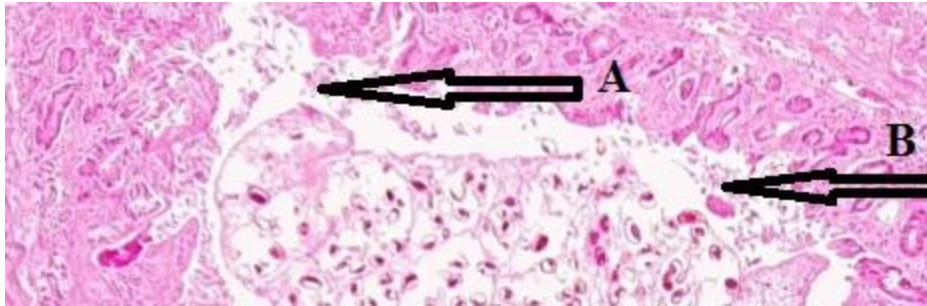glands, and tissue nodularity were also observed (Figures 3 and 4). The accumulation of neutrophils and eosinophils was evident in damaged liver tissues and bile ducts (Figure 5).



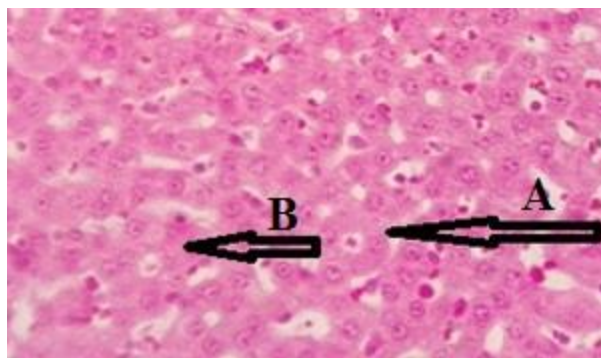
**Figure 1.** The histological section of an infected liver. A: eggs in bile ducts. B: the histological section of *dicrocoelium* worm (tip of arrow, 40x magnification, H&E staining).



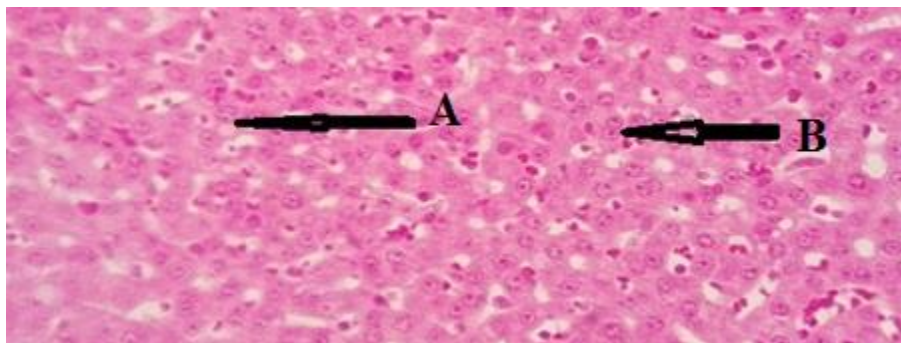
**Figure 2.** The histological section of an infected liver. A, B: swelling of bile duct mucosal glands due to *dicrocoelium* infection (arrow, 40x magnification, H&E staining).



**Figure 3.** The histological section of an infected liver. A, B: destruction of the epithelial tissue of infected liver due to contact with *dicrocoelium* (arrows, 40x magnification, H&E staining).



**Figure 4.** The histological section of an infected liver. A, B: hyperplasia of bile ducts' mucosal glands (arrows, 40x magnification, H&E staining).



**Figure 5.** The histological section of an infected liver. A, B: inflammatory cells (neutrophil and eosinophil) infiltration in the infected liver (arrows, 40x magnification, H&E staining).

### Molecular analysis

Following PCR amplification of 28S rDNA, all *dicrocoelium* samples showed 963-bp bands, and no amplification was observed in the negative control (Figure 6). In RFLP and

after digestion with the TruII restriction enzyme, four band patterns including 116 bp, 145 bp, 293 bp, and 409 bp were observed (Figure 7). According to these band patterns, all the samples were identified as *D. dendriticum*.

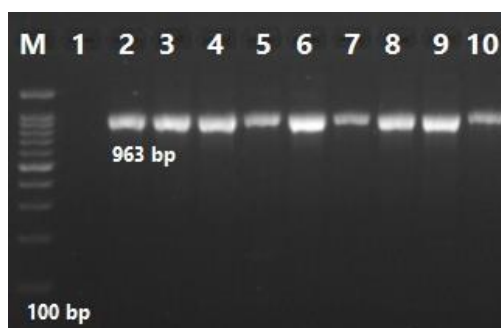


Figure 6. PCR amplification of *Dicrocoelium* 28S rDNA. M: 100-bp DNA marker, line 1: negative control, lines 2, 5, 8: cattle isolates from Ilam, Kermanshah, and Kurdistan provinces, respectively, lines 3, 6, 9: sheep isolates from Ilam, Kermanshah, and Kurdistan provinces, respectively, and lines 4, 7, 10: goat isolates from Ilam, Kermanshah, and Kurdistan provinces, respectively.

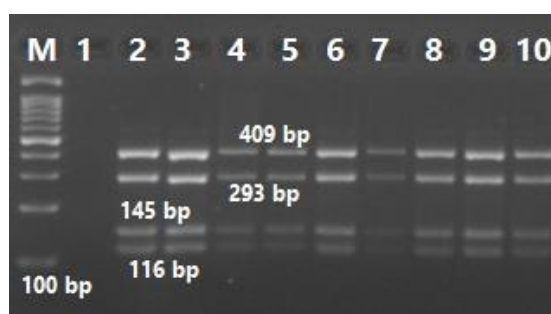


Figure 7. PCR-RFLP patterns of *Dicrocoelium* 28S rDNA digested by the TruI restriction enzyme. M: 100-bp DNA marker, line 1: negative control, lines 2,5,8: cattle isolates from Ilam, Kermanshah, and Kurdistan provinces, respectively, lines 3,6,9: sheep isolates from Ilam, Kermanshah, and Kurdistan provinces, respectively, and lines 4, 7,10: goat isolates from Ilam, Kermanshah, and Kurdistan provinces, respectively.

Sequencing of the amplicons revealed no differences in the nucleotide sequence of 28S rDNA among different hosts and sampling locations. After sorting, the sequences were registered in the World Gene Bank with the accession numbers of MT539114, MT539115, and MT539116.

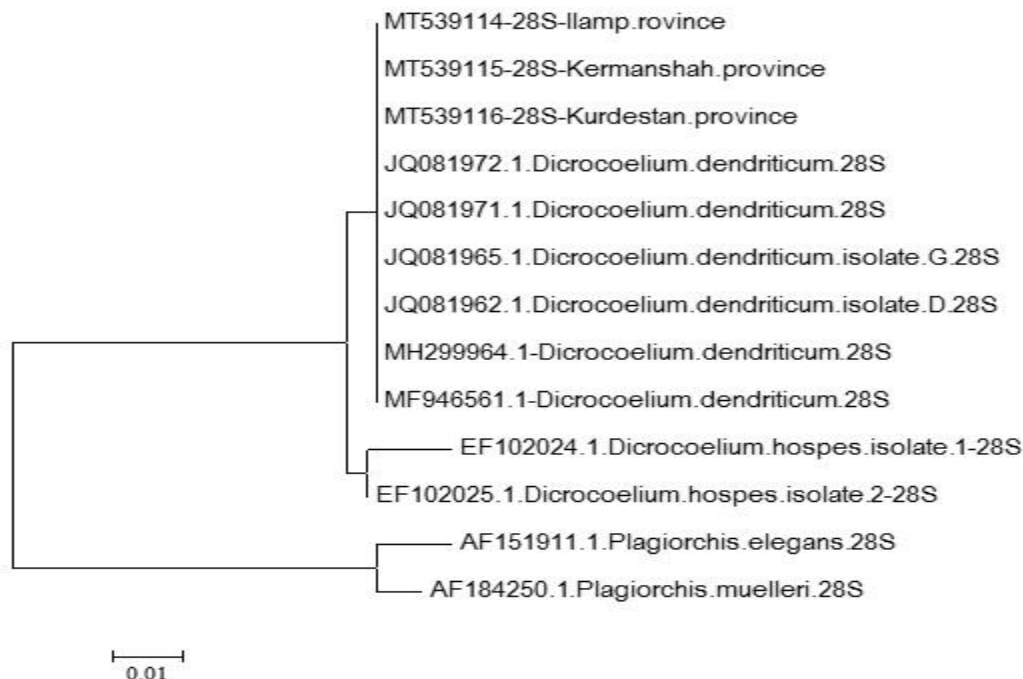
Matching the sequences with each other and those registered in the World Gene Bank (MH299964.1 and MF946561.1) showed a similarity between 97% and 100% (Figure 8). The results of the present study, based on the genotyping of 28S rDNA sequences, showed that *D. dendriticum* was the only species of *Dicrocoelium* genus infecting domestic animals in three western provinces of Iran; Ilam, Kermanshah, and Kurdistan. Accordingly, the dominant haplotype of *D. dendriticum* in western Iran was named as "A".

## Discussion

Infection with *dicrocoelium* has great impacts on the livestock production in the locations where the infection is endemic. Therefore, prevention, detection, and control of the infection are particularly important to maintain the economic benefits of breeding herbivorous animals (7). The results of the present study showed that *D. dendriticum* was the only species of this genus which was isolated from all evaluated hosts in the three different regions studied. Macroscopic observation of infected livers showed swelling, discoloration, dark-red colonies, needle-shape spots, stiffness, muscularization, shrinkage, liver margins sclerosis, and severe biliary fibrosis. These were in line with the results of Islami *et al.* (26). Microscopic evaluation of the liver

tissue demonstrated bile duct swelling and mucosal gland hyperplasia along with the presence of adult worms and their eggs in histologic sections. This was also consistent with the findings of Changizi *et al.* (27). In another study, numerous worms in bile ducts, white spots on the surface of the liver, swollen hepatocytes, thick ducts, and liver cirrhosis were reported (28), which is

consistent with our findings. In the study of Amniattalab *et al.* in Urmia, the most prominent microscopic lesions were hyperemia and hyperplasia of bile duct mucosal glands (29), which were also in line with the results of the present study. In Iran, the chronic form of Dicrocoeliasis is usually observed in ruminants, so liver tissue destruction is not extensive.



**Figure 8.** The phylogenetic tree of the obtained fragments in comparison with the homologous sequences registered in the Gene Bank database. It was designed by Mega v.6 program using maximum likelihood method, supported by 2000 bootstrap replications.

In molecular methods, DNA sequencing provides an alternative approach to identify haplotypes of parasites. Different target sequences may be used for phylogenetic and polymorphism studies, but rDNA is a powerful tool to demonstrate substantial intra and inter specific variabilities among distinct parasite species because it includes highly conserved regions as well as sequences with varying degrees of evolutionary alterations (8). So, we used 28S rDNA for differential diagnosis and determining interspecific differences between the *D. dendriticum*

isolated from various hosts in different locations in west of Iran. In the molecular analyses conducted by Gorjipour *et al.* and Otranto *et al.*, no differences were observed in the nucleotide sequences of 28S rRNA coding genes between the studied samples (18, 30). In addition, Morley *et al.* used 28S rDNA and ITS2 genes to differentiate *D. dendriticum* and *D. haspes* and found no intra species diversity in 28S rDNA sequence of *D. dendriticum* after matching the sequences with those available in the Gene Bank (8). However, there was a difference of about 8.2

to 8.5% in ITS2 sequence between *D. dendriticum* and *D. chinensis*, that can be used to differentiate these species from each other (8). The molecular analysis of 28S rDNA gene of *dicrocoelium* by Arbabi *et al.* and Bari *et al.* revealed a genetic similarity of about 98-99% among the studied isolates (31,32), which was consistent with the molecular results of the present study. In a study in 2014, Leo *et al.* assessed the degree of genetic similarity between *D. dendriticum* and *D. chinensis* based on the nucleotide sequences of ITS2 and 28S rDNA genetic markers and reported a great difference between the two species regarding the sequence of ITS2 gene, but not 28S rDNA (33). Gorjipour *et al.* also studied *dicrocoelium* diversity in ruminants based on the nucleotide sequence of ITS2 gene and identified two different haplotypes (A and B) of *D. dendriticum*, the ITS-A being the dominant haplotype (18). Our findings will provide basic information for further studies on the molecular epidemiology and control of *D. dendriticum* in different parts of Iran.

## References

1. Moshfe A, Bagheri M, Mohebi Nobandegany Z. [Prevalence of *Fasciola hepatica* in slaughtered livestock in Yasuj slaughterhouse 2001-2002]. *Armaghan-e- Danesh J.* 2003; 8(30):25-33. (In Persian)
2. Marquardt WC, Demaree SR, Grive RB. *Parasitology vector biology.* 2<sup>th</sup> ed. San Diego Harcourt Academic Publication. 2000; P.273-285.
3. Campo R, Manga gonzalez MY, Gonzalez lanza C. Relationship between egg output and parasitic burden in lambs experimentally infected with different doses of *Dicrocoelium dendriticum*. *Vet Parasitol.* 2000; 87(2-3): 139-49. doi:10.1016/S0304-4017(99)00165-X.
4. Heussler V, Kaufmann H, Glaser I, Ducommun D, Muller C, Dobbelaere D.

## Conclusion

The findings of the present study showed that *D. dendriticum* was the only species of *dicrocoelium* identified in the samples collected from cattle, sheep, and goats in three western provinces of Iran (Ilam, Kermanshah, and Kurdistan). Molecular analysis of the nucleotide sequence of 28S rDNA gene revealed no genetic differences among the isolates. Regarding the economic and health importance of dicrocoeliasis, it is suggested to more extensively study the prevalence and incidence of this disease. Also, more studies are required to accurately identify and differentiate the parasite isolates based on the sequencing of other relevant genes.

## Aknowledgments

This research was supported by Science and Research Branch, Islamic Azad University (grant number 1535334).

- A DNA probe for the detection of *Dicrocoelium dendriticum* in ants of *Formica* spp. and *Lasius* spp. *Parasitol Res.* 1998;84(6):505-8. doi:10.1007/s004360050437.
5. Jeandron A, Rinaldi L, Abdylidaeva G, Usubaliev J, Steinmann P, Cringoli G, et al. Human infections with *Dicrocoelium dendriticum* in Kyrgyzstan the tip of the iceberg? *J Parasitol.* 2011; 97(6): 1170-3. doi:10.1645/GE-2828.1.
6. Zhao GH, Bian QQ, Ren WX, Jia YQ, Cheng WY, Fang YQ, et al. Genetic variability among *Dicrocoelium dendriticum* isolates from different regions in Shaanxi province China revealed by sequences of three mitochondrial genes. *Mitochondrial DNA.* 2013;24(6): 683-8.



7. Manga-Gonzalez MY, Gonzalez Lanza C, Cabanas E, Campo R. Contributions to and review of dicrocoeliosis with special reference to the intermediate hosts of *Dicrocoelium dendriticum*. *Parasitology*. 2001; 123(7): 91-114.
8. Maurelli MP, Rinaldi L, Capuano F, Perugini AG, Veneziano V, Cringoli G. Characterization of the 28S and the second internal transcribed spacer of ribosomal DNA of *Dicrocoelium dendriticum* and *Dicrocoelium hospes*. *Parasitol Res*. 2007; 101(5): 1251-5. doi:10.1007/s00436-007-0629-1.
9. Nezami E, Arbabi M, Hooshyar H, Delavari M. Morphological and molecular detection of *dicrocoelium dendriticum* isolated from domestic animals based on genetic nd1 marker in Markazi province. *J Vet Res*. 2019; 74(1): 27-34.
10. Bari S, Sarvi S, Daryani A, Ziaeeihezarjaribi H, Arbabi M, Pirestani M, et al. [*Dicrocoelium dentriticum* infection among domestic animals in iran: A systematic review and meta-analysis]. *J Mazandaran Uni Med Sci*. 2016; 25(132): 367-375. (In Persian)
11. Manga gonzalez MY, Quiroz romero H, Gonzalez lanza C, Minambres B, Ochoa P. Strategic control of *Dicrocoelium dendriticum* egg excretion by naturally infected sheep. *Vet Med*. 2010;55(1):19-29. doi:10.17221/63/2009-VETMED.
12. Nguyen TG, Vande N, Vercruyssen J, Dorny P, Lee TH. Genotypic characterization and species identification of *Fasciola* spp. With implications regarding the isolates infecting goats in Vietnam. *Exp Parasitol*. 2009; 123: 354-61. doi: 10.1016/j.exppara.2009.09.001.
13. Sandoval H, Manga gonzalez MY, Castro JM. A tool for diagnosis of *Dicrocoelium dendriticum* infection hatching eggs and molecular identification of the miracidium. *Parasitol Res*. 2013;112(4): 1589-95. doi:10.1007/s00436-013-3313-7.
14. Kleiman F, Pietrokovsky S, Prepelitchi L, Carbajo AE, Wisnivesky C. Dynamics of *Fasciola hepatica* transmission in the Andean Patagonian valleys Argentina. *Vet Parasitol*. 2007; 14(5):274-86. doi:10.1016/j.vetpar.2006.12.020.
15. Meshgi B, Khodaveisi M. Determination of immunodominant antigens of *Dicrocoelium dendriticum* by hyperimmune sera. *Immunol Infect Dis*. 2014;2: 4-8. doi:10.1017/S0022149X20000565.
16. Jahedkhaniki GhR, Beigomkia E, Raei M. Liver condemnation and economic losses due to parasitic infections in slaughtered animals in Iran. *J Parasit Dis*. 2013; 37:240-4. doi:10.1007/s12639-012-0172-6.
17. Farid H. Human infection with *Fasciola hepatica* and *Dicrocoelium dendriticum* in Isfahan area Central Iran. *J Parasitol*. 1971; 57(1):83-8. doi:10.2307/3277773.
18. Gorjipoor S, Moazeni M, Sharifiyazdi H. Characterization of *Dicrocoelium dendriticum* haplotypes from sheep and cattle in Iran based on the internal transcribed spacer 2 and NADH dehydrogenase gene. *J Helminthol*. 2015;89(2): 158-64. doi:10.1017/S0022149X13000679.
19. Eslami A. *Veterinary helminthology trematodes*. 1<sup>th</sup> ed. Tehran Uni Publication. 1998; P.50-106. (In Persian).
20. Shamsi M, Dalimi A, Khosravi A, Ghafarifar F, Pourahmad F. Determination and Sequencing of genotypes of *Echinococcus granulosus* from stray dog's isolates with cox1 gen in Ilam West of Iran. *Sci J Ilam Uni Med Sci*. 2017; 24(6):97-106. (In Persian) doi: 10.18869/acadpub.sjim.24.6.97.
21. Shamsi M, Dalimi A, Khosravi A, Ghafarifar F. The phylogenetic similarity

- of *hydatid cyst* isolated from humans and sheep in Ilam Province Southwest of Iran. *Comp Clin Pathol.* 2016; 25:1221-6. doi:10.1007/s00580-016-2332-z.
22. Dalimi A, Shamsi M, Khosravi A, Ghaffarifar F. Genotyping *Echinococcus granulosus* from canine isolates in Ilam province West of Iran. *Iran J Parasitol.* 2017; 12(4): 614-21.
23. Sandoval H, Manga gonzalez Y, Campo R, Garcia P, Castro JM, Perez M. Preliminary study on genetic variability of *Dicrocoelium dendriticum* determined by random amplified polymorphic DNA. *Parasitol Int.* 1999; 48: 21-6. doi:10.1016/S1383-5769(98)00035-X.
24. Bowles J, McManus DP. Rapid discrimination of *Echinococcus* species and strains using a polymerase chain reaction-based RFLP method. *Mol Biochem Parasitol.* 1993; 57: 231-9. doi:10.1016/0166-6851(93)90199-8.
25. Tamura K, Peterson D, Peterson N, Stecher G, Nei M, Kumar S. MEGA5 molecular evolutionary genetics analysis using maximum likelihood, evolutionary distance and maximum parsimony methods. *Mol Bio Evol.* 2011;28: 2731-9. doi:10.1093/molbev/msr121.
26. Eslami A. *Parasitology helminthology*. 3<sup>th</sup> ed. Tehran Publication. 2004.
27. Chngizi A, Sohrabihaghdoust E, Eslami A, Moghadam M. Prevalence, frequency distribution and pathology of *Dicrocoelium dendriticum* in cape here *Lepus copensis* of Iran. *Pajohesh Sazandegi.* 1998; 39:135-7. (In Persian)
28. Jithendran KP, Bhat TK. Prevalence of *Dicrocoeliosis* in sheep and goats in Himachal Pradesh India. *Vet Parasitol.* 1996;61(3-4): 265-71. doi:10.1016/0304-4017(95)00834-9.
29. Amniyattalab A. Manaffar A. Histological pathology of gallbladder lesions in the livers recorded from slaughtered cows in Urmia industrial slaughterhouse. *Tabriz Vet Clin Pathol.* 2015; 9(3):215-7. (In Persian)
30. Otranto D, Rehbein S, Weigl S, Cantacessi C, Parisi A, et al. Morphological and molecular differentiation between *Dicrocoelium dendriticum* and *Dicrocoelium chinensis* Platyhelminthes digenea. *Acta Tropica.* 2007; 104(2-3):91-8. doi:10.1016/j.actatropica.2007.07.008.
31. Arbabi M, Dalimiasl A, Ghaffarifar F, Foorozandeh-Moghadam M. Morphological and molecular characterization of *Dicrocoelium* isolated from sheep in the north and center of Iran. *Feyz J Kashan Uni Med Sci.* 2012;16(2):42-7. (In Persian)
32. Bari S, Arbabi M, Gill P, Sharif M, Ziaeihezjararibi H, Dodangeh S, et al. Morphological and molecular 28S rDNA characterization of *Dicrocoelium dendriticum* isolates from sheep goat and cattle in Mazandaran province Iran. *J Mazandaran Uni Med Sci.* 2018; 28(159):38-45. (In Persian)
33. Liu GH, Yan HB, Otranto D, Wang XY, Zhao GH, Jia WZ, et al. *Dicrocoelium chinensis* and *Dicrocoelium dendriticum* are distinct lancet fluke species based on mitochondrial and nuclear ribosomal DNA sequences. *Mole Phylogenet Evol.* 2014;79: 325-31. doi: 10.1016/j.ympev.2014.07.002.