

**Low hemoglobin level is the major cause of pain and hallux blur: A clinical case report**Behnaz Nateghi<sup>1,2</sup>, Reyhaneh Rabieian<sup>1,2,3</sup>, Mansoor Salehi<sup>1,2,3\*</sup>

1. Medical Genetics Research Center of Genome, Isfahan University of Medical Sciences, Isfahan, Iran
2. Cellular, Molecular, and Genetics Research Center, Isfahan University of Medical Sciences, Isfahan, Iran
3. Department of Genetics and Molecular Biology, School of Medicine, Isfahan University of Medical Sciences, Isfahan, Iran

**\*Corresponding author:** Tel: +98 3136246922 Fax: +98 3136258320

Address: Cellular, Molecular, and Genetics Research Center, Isfahan University of Medical Sciences, Isfahan, Iran. Medical Genetics Research Center of Genome.

E-mail: M\_salehi@med.mui.ac.ir

Received; 2/11/2019 revised; 15/12/2019 accepted; 25/12/2019

**Abstract**

Chronic lymphocytic leukemia (CLL) is the most common leukemia in adults. Anemia is world health problems and common medical conditions seen in clinical practice. We report the case of a 47-years-old woman who presented pain and obvious changes in hallux. With regard to available symptoms, special issues like strike, CLL, banned veins of foot and occult blood was guessed as a general mechanism of disease. But the result of performed tests and the effect of used drugs exclude all mentioned problems and low hemoglobin level was recognized as the only crucial cause of disease. With according to the results of blood counts and symptoms, disease for CLL, after performing tests and treatment of disease with iron supplementation, we recognized that particularly iron deficiency is the essential cause of disease.

**Keywords:** Hemoglobin, Blood, Cell blood count**Introduction**

Chronic lymphocytic leukemia (CLL) is a malignancy of CD5<sup>+</sup> B cells that mature-appearing neoplastic lymphocytes in the blood, marrow and secondary lymphoid tissues (1). CLL in men than women, with a sex ratio of about 1.5-2:1 is common more (2). Anemia is roughly a third of the world's population, half the cases are due to iron deficiency (3). Here we report the case of a 47-years-old woman who presented pain and obvious changes in hallux.

**Case report**

A 47-years-old woman with no history of any disease, and severe pain in left hallux

referred to laboratory. In primary checking because of hallux and nail blur it was probably guessed as a strike, so imaging the left foot was performed (Figure 1).

As regards, injury probability was eliminated by imaging, complete blood count (CBC) test was performed to evaluate the other situations. The results of this test revealed low level of various factors in the blood like hemoglobin by 5/7gr/dl, in normal ranges of 11/5-16/5gr/dl and high level of platelets by 683 in in normal ranges of 150-450. In order to ensure these results, CBC test was replicated that it confirmed the results of the primary test (Table 1). 500cc of blood was injected into the patient,

**Copyright © 2019 Journal of Basic Research in Medical Science.** This is an open access article distributed under the terms of the Creative Commons Attribution 4.0 International License (<https://creativecommons.org/licenses/by-nc/4.0/>) which permits copy and redistribute the material, in any medium or format, provided the original work is properly cited.

and then CBC test was performed again, for measuring the changes of blood factors,

which showed relative improvement.

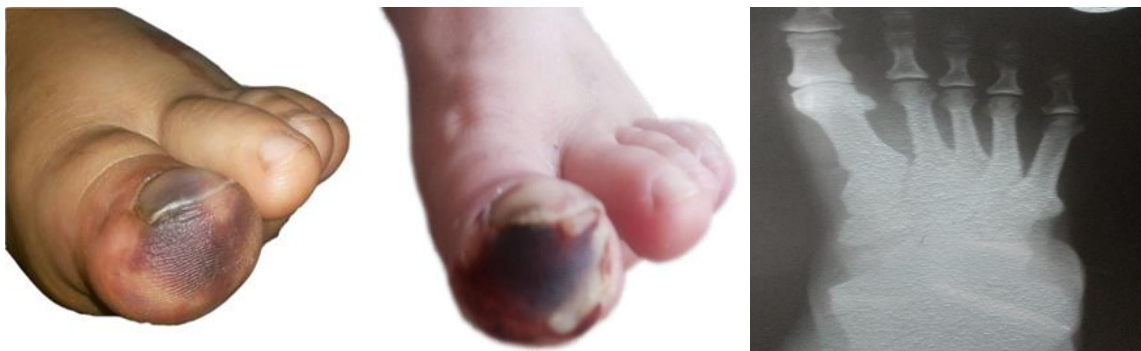

Figure1. Imaging the left foot.

Table 1. Hematological parameters.

Test	Result	Normal range
WBC	14.1	4-10
RBC	4.06	Females: 3.9-5.6
Hemoglobin	5.7	Females: 11.5-16.5
Haematocrit	21.4	Females: 36-47
PLT	683	150-450

WBC: white blood cells, RBC: red blood cells, PLT: platelets.

In addition, for determining the cause of anemia and foot pain various tests include hemoglobin Electrophoresis, blood sugar, keratin, Uric acid, Nitrogen, blood uric and occult blood was done, which all results of tests were normal and occult blood were not detected. With regard to previous normal result tests and existence of symptoms, it was decided that the patient was examined

for Chronic lymphocytic leukemia (CLL), so genetic testing of ABL-BCR, JAK2 was performed, and the results of two tests were negative .Moreover, to examine the cause of hallux blur, color Doppler sonography was used to assess blood flow and cysts which results showed that veins was completely normal and there wasn't any cysts (Figure 2).

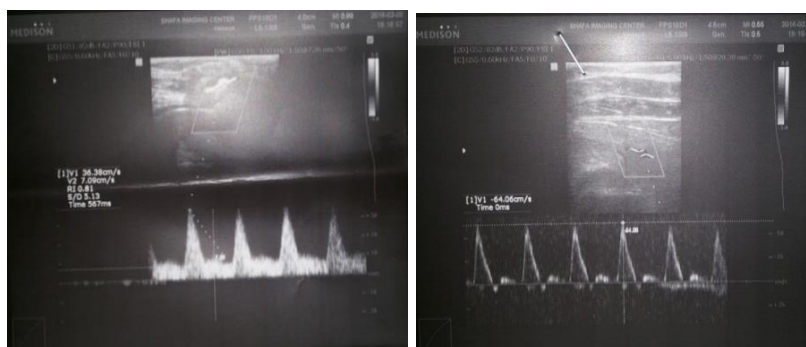


Figure 2. Color Doppler sonography of venous.

The patient consumed daily oral iron for two months, after this time re-testing of C.B.C was done that blood elements

moderately increased and after this treatment the patient's condition much improved, hemoglobin by 10 gr/dl

and level of platelets by 464. Therefore, low hemoglobin level was detected as the only a key mechanism of this disease.

### Discussion

CLL is the most common type of leukemia in Western countries and mainly affects the elderly (4). Recently, an increased incidence of CLL has been reported among young people that about one-third of the new cases is diagnosed before the age of 55 years. Oftentimes disease is asymptomatic that with routine tests such as complete blood count (CBC) was detected. In contrast, in some of the situations, patients have shown symptoms such as an expanding population of malignant cells in the bone marrow and peripheral blood, and are faced with fatigue and exercise intolerance caused by progressive anemia (3). Iron deficiency and anemia are world

health problems and common medical conditions seen in clinical practice. Although the prevalence of iron deficiency declined recently, but it remains high in the rankings over the world and have a significant impact on the lives of children and pre-menopausal women in the both poor and developing countries (5). Iron in the form of hemoglobin is vital for many metabolic actions such as an oxygen transporter (6). In this report, we faced with a case that according to the results of blood counts and symptoms, disease was examined for CLL and other situations. After performing tests and treatment of disease with iron supplementation for two months, we recognized that particularly iron deficiency is the essential cause of disease. Sometimes iron deficiency anemia symptoms can be similar to CLL. In these cases, more accurate tests should be done.

### References

1. Kipps TJ, Stevenson FK, Wu CJ, Croce CM, Packham G, Wierda WG, et al. Chronic lymphocytic leukaemia. *Nat Rev Dis Primers*. 2017; 3:17008. doi: 10.1038/nrdp.2017.8.
2. Ghia P, Ferreri AM, Caligaris-Cappio F. Chronic lymphocytic leukemia. *Crit Rev Oncol Hematol*. 2007; 64(3):234-46. doi: 10.1016/j.critrevonc.2007.04.008.
3. Lopez A, Cacoub P, Macdougall IC, Peyrin-Biroulet L. Iron deficiency anaemia. *Lancet*. 2016; 387(10021):907-916. doi: 10.1016/S0140-6736(15)60865-0.
4. Dighiero G. Chronic lymphocytic leukemia treatment. *Hematol Cell Ther*. 1997;39: S31-S40 (1997). doi: 10.1007/s00282-997-0031-6.
5. Longo DL, Camaschella C. Iron-deficiency anemia. *N Engl J Med*. 2015; 372(19):1832-43. doi: 10.1056/NEJMra1401038.
6. Naigamwalla DZ, Webb JA, Giger U. Iron deficiency anemia. *Can Vet J*. 2012; 53(3): 250-6.