

**Effect of naproxen on postoperative pain in teeth with irreversible pulpitis**

Maryam Raof<sup>1</sup>, Atieh Sadr<sup>2</sup>, Farahnaz Nazari<sup>3\*</sup>, Sara Amanpour<sup>4</sup>, Masoud Nazeri<sup>5</sup>, Saeedeh Sadr<sup>6</sup>, Sedigheh Farzaneh<sup>3</sup>, Jahangir Haghani<sup>1</sup>, Maryam Rad<sup>7</sup>

1. Laboratory of Molecular Neuroscience, Neuroscience Research Center, Institute of Neuropharmacology, Kerman University of Medical Sciences, Kerman, Iran
2. School of Dentistry and Health Sciences, Charles Sturt University, Sydney, Australia.
3. Department of Endodontics, School of Dentistry, Kerman University of Medical Sciences, Kerman, Iran
4. Department of Oral and Maxillofacial Pathology, School of Dentistry, Kerman University of Medical Sciences, Kerman, Iran
5. Department of Oral Medicine, School of Dentistry, Kerman University of Medical Sciences, Kerman, Iran
6. Persian Gulf Oral and Dental Diseases Research Center, Hormozgan University of Medical Sciences, Bandar Abbas, Iran
7. Oral and Dental Diseases Research Center, Kerman University of Medical Sciences, Kerman, Iran

\*Corresponding author: Tel: +98 9133416108 Fax: +98 3432118073

Address: Department of Endodontics, School of Dentistry, Shafa St, Jomhoori Eslami Blvd, Kerman, Iran

E-mail: Raofm56@yahoo.com

Received; 2015/06/10 accepted; 2015/06/24

**Abstract**

**Introduction:** Effective post-operative pain management is one of the problems following root canal treatment. Nonsteroidal anti-inflammatory drugs (NSAIDs) are the most commonly prescribed analgesics in endodontics. The aim of this study was to evaluate the effectiveness of naproxen in controlling pain following root canal treatment in teeth with irreversible pulpitis.

**Materials and methods:** This triple-blinded clinical trial was performed on 68 patients admitted to dental school for root canal treatment (RCT). Patients were randomly allocated to treatment or placebo groups. After performing RCT, the patients received naproxen (275 mg every 12 hours for 48 hours) or placebo. Patients were instructed to complete a VAS pain score at 6, 12, 24, 48 and 72 h after single visit root canal treatment. Patients were classified as having no, mild, moderate, or severe pain. Data were analyzed via SPSS software using chi-square and t-test.

**Results:** Although there was a significant difference between naproxen prescription compared with placebo in 6 and 72 hour intervals, the effect of naproxen in controlling post endodontic pain in all intervals was more than placebo. In addition, the duration of pain was shorter in the subjects receiving naproxen.

**Conclusion:** Based on the results of the present study, naproxen could be suggested to control post endodontic pain in patients with irreversible pulpitis.

**Keywords:** Root canal treatment, Postoperative pain, Naproxen, Irreversible pulpitis

**Introduction**

Pain after root canal treatment (RCT) is a major concern for both patients and clinicians (1). The prevalence of post-operative pain in different studies is estimated to be 10.6 %- 82.9% (2).

Different factors contribute to the development of post-operative pain, including: the tooth affected, age, sex, a previous experience, psychological factors, immunologic factors, unadjusted

temporary restoration, microbial factors, chemical cytokines, intraoperative factors and increased periapical tissue pressure (2-4).

A variety of studies have evaluated the efficacy of different strategies to control post-operative pain in endodontics (3, 5, 6). Commonly used methods are considered administration of long acting anesthetics and using analgesic drugs. Numerous investigations have demonstrated that regular administration of analgesics following RCT could reduce post-operative pain (7,8). However, Pariokh et al. (2014) have shown that regular administration of Ibuprofen after RCT in patients, who had irreversible pulpitis without moderate to severe spontaneous pain, had no significant effect on pain relief compared with an on-demand regimen up to 48 hours after treatment (9).

Non-steroidal anti-inflammatory drugs (NSAIDs) are the most common agents used to control post-operative pain (8). They inhibit Cyclo-oxygenase enzyme and thus prevent the catalysis of Arachidonic acid to prostaglandins, one of the most important chemical agents involved in pain and inflammation (1). Ibuprofen is the drug of choice to reduce pulpal inflammation and pain (2, 7). Onset of action is longer for Naproxen compared to that for Ibuprofen. However, the duration of analgesia obtained with Naproxen is higher than Ibuprofen (10).

Due to the fact that maximum pain following RCT is observed within the first 24 hours (11), Naproxen could be a good candidate to reduce pain in the patients. Furthermore, naproxen has the minimal cardiovascular side effects amongst NSAID's (12). Regarding the increasing prevalence of cardiovascular diseases; naproxen seems to be a good candidate to control post-operative pain .

Wells et al. (2006) determined the efficacy of Ibuprofen and ibuprofen/acetaminophen on postoperative pain in symptomatic patients with a pulpal diagnosis of

necrosis. There was no statistically significant difference between the 2 groups for analgesic use or escape medication use. (13). Another study compared the effects of single doses of Tramadol, Novafen and Naproxen on postoperative pain following instrumentation of root canals in teeth with irreversible pulpitis. All three agents reduced post-operative pain, though tramadol was significantly less effective than naproxen, and novafen that were similar to each other (1). In the study by Gottesdiener et al. also, naproxen was efficacious in the treatment of postoperative pain after surgical removal of third molars. (14).

Regarding the noticeable benefits of naproxen including few side effects, accessibility, relative low price and considering the fact that there is no study evaluating the efficacy of regularly scheduled administration of naproxen on endodontic post-operative pain, the aim of the current study was to determine the analgesic effect of naproxen administration following root canal treatment of teeth with the diagnosis of irreversible pulpitis.

### Materials and methods

Sixty-eight patients participated in this triple-blinded randomized clinical trial that was approved by the Ethics Committee of Rafsanjan University of Medical Sciences. The inclusion criteria included: no systemic diseases, no detected sensitivity to 2% lidocaine with 1:80,000 epinephrine and NSAID's, having an asymptomatic molar with the diagnosis of irreversible pulpitis .

Exclusion criteria of participation in this study were: pregnancy, lactation, and patients younger than 18 or older than 40 years of age .

After explaining the procedure of treatment, the written informed consents were obtained from the patients. Naproxen (275 mg) and placebo tablets were provided by Pars Darou Company and were matched in size and shape. The

packaging of an actual generic analgesic drug was used for. Immediately after root canal treatment, patients were randomly given 12 tablets of either naproxen or placebo. Patients, clinician and statistician were all blinded to treatment allocation .

Under local anesthesia with 2% lidocaine and 1/80000 epinephrine, an access cavity was made. Following isolation with rubber dam, cleaning and shaping was performed using passive step back technique. Irrigation was performed with normal saline. Obturation was done using cold lateral condensation technique with gutta percha (Arya dent, Iran) and ZOE sealer. All the cases were treated in a single visit. The pain ratings were explained to the patients before injection. The patients were asked to grade their pain on a Heft-Parker Visual Analogue Scale (VAS) with 170-mm line. The millimeter marks were removed from the scale, and the scale was divided into 4 categories with various terms describing the level of pain: no pain corresponded to 0 mm; faint, weak, or mild pain corresponded to 1–54 mm; moderate pain corresponded to 55–114 mm; and strong, intense, and maximum possible pain corresponded to more than 114 mm (13).

The patients were advised to take one tablet immediately after treatment, followed by another tablet every 6 hours

for 72 hours. Subjects were also asked to record their pain scores at 6, 12, 24, 48 and 72 hours after treatment. Patients who experienced severe pain were excluded from the study and received extra analgesics .

Statistical analysis consisted of Student's t test and chi-square analysis on a software program SPSS (IBM, USA) for Windows ver. 16.0.  $P < 0.05$  was considered statistically significant.

## Results

Six patients were excluded from the study due to incomplete pain record or taking extra drugs. Data of 62 patients (32 in Naproxen group, 30 in placebo group) were analyzed. There were no significant differences between the groups in terms of demographic variables (age, sex and the kind of treated tooth) ( $p > 0.05$ ).

Table 1 shows the percentage of patients in different pain intensity categories. As shown in table and figure 1, the percentages of patients having a moderate or severe pain at all time intervals were higher in placebo group than that of naproxen-treated subjects. These differences were statistically significant at 6 and 72 hours post-operative intervals ( $p < 0.05$ ).

**Table 1.** The percentage of patients in different pain intensity categories in naproxen and placebo groups.

Time post-treatment	Group	No pain	Mild pain	Moderate pain	Severe pain
6h	Naproxen	36.7	33.3	30	0
	Placebo	15.6	31.3	37.5	15.6
12h	Naproxen	43.3	26.7	26.7	3.3
	Placebo	31.3	25	28.1	15.6
24h	Naproxen	56.7	23.3	16.7	3.3
	Placebo	31.3	34.4	15.6	18.8
48h	Naproxen	66.7	30	3.3	0
	Placebo	46.9	31.3	12.5	9.4
72h	Naproxen	83.3	10	6.7	0
	Placebo	53.1	25	9.4	12.5

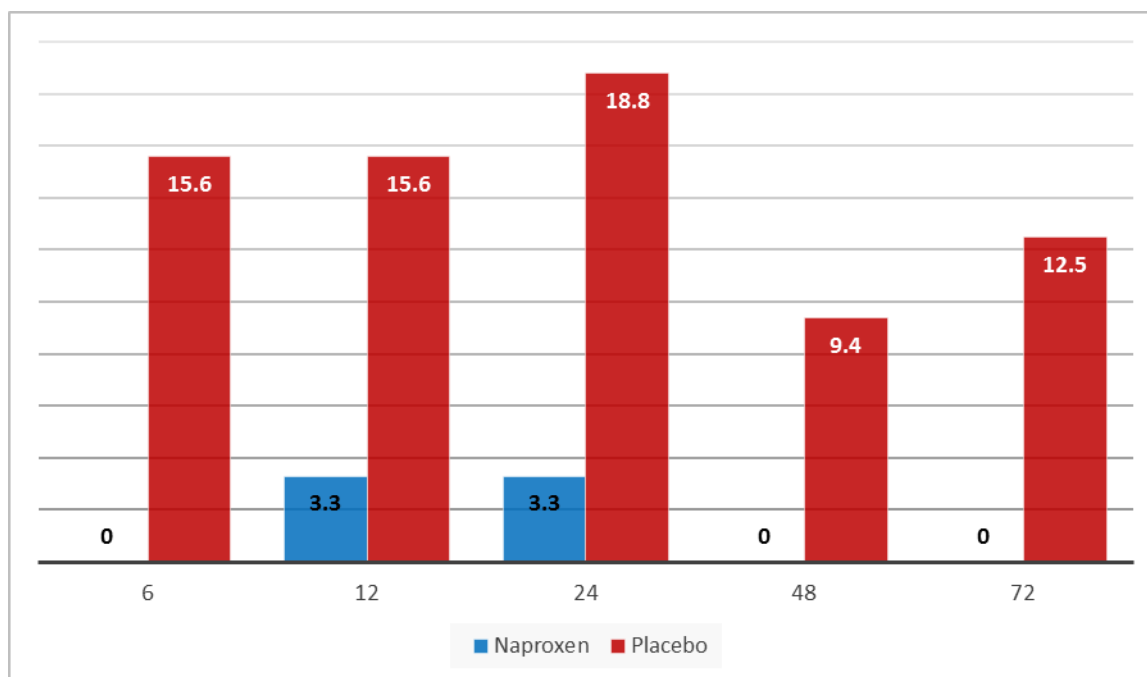


Figure 1: Comparison of sever pain between the two groups at 6, 12, 24, 48 and 72 hours post treatment.

## Discussion

Pain during and subsequent to root canal treatment (RCT) may lead to patient dissatisfaction with medical service, evoke fear of dental treatments and act as a barrier to adherence and willingness to continue treatment. Hence effective pain control is of great importance in endodontics (15). In the present study, the administration of naproxen postoperatively reduced pain for teeth with asymptomatic irreversible pulpitis.

One of the factors contributing to the development of pain after RCT is the trauma directly applied to the periodontium. This event leads to membrane degradation of vascular and cellular structures and release of some inflammatory cytokines including prostaglandins (PG), and thromboxanes (TX). The formation of each inflammatory cytokines is associated with pain after RCT procedure (16, 17). Naproxen is a nonselective COX-1 and COX-2 inhibitor and therefore exerts its analgesic effect through peripheral inhibition of the production of PG's and TX's (1).

In a study by Sanders et al. on patients with hand pain in osteoarthritis, significant reductions in brain activity following treatment with naproxen, compared to placebo, were observed in brain regions commonly associated with pain perception, including the bilateral primary somatosensory cortex, thalamus, and amygdala. Significant relationships between changes in perceived pain intensity and changes in brain activity were also observed in brain regions previously associated with pain intensity (18). Hence it seems rationale to observe pain reduction following administration of naproxen immediately after RCT .

In the current research, Pain levels were evaluated within the first 72 hours after RCT. This time window was selected based on the fact that the maximum pain intensity is experienced within the first 24 hours and pain usually subsides within 72 hours (11).

None of the patients reported adverse effects associated with the use of Naproxen. This is in part due to the fact that the patients didn't have prior systemic

disease. Moreover, this trial was limited by the short duration of drug administration. However, long-term use of naproxen has been associated with increased incidence of gastrointestinal side-effects (19).

The analgesic efficacy of placebo was significantly lower than that of naproxen in 6 and 72 hours post-treatment. A larger sample size and higher doses of naproxen may lead to more significant differences between the two groups. However, in accordance with previous studies we propose that placebo analgesia, including physiological phenomena, is a facet of pain perception (20, 21).

Polat et al. (2005) evaluated the effects of preoperative ibuprofen and naproxen sodium on orthodontic pain. The results revealed that patients taking 550 mg naproxen sodium one hour before archwire placement had significantly lower levels of pain at two hours, six hours, and nighttime after adjustment than patients taking placebo or ibuprofen (22). In another study, there was no significant difference between rofecoxib and naproxen in controlling post-surgical dental pain (23). In the study by Björnsson et al., naproxen was superior to acetaminophen at 8, 12, and 16 hours on the 1st postoperative day and at 8 hours on the 2nd postoperative day, when the pain intensity was lower than that on the first day of third molar surgery (24). Moreover, similar to our study, Mehrvarzfar et al. found that naproxen taken immediately after treatment reduced postoperative pain following pulpectomy and root canal preparation of teeth with irreversible pulpitis. However, they used a single oral dose of the analgesics (1).

The maximum postoperative endodontic pain level experienced by patients has been reported within the first two to 10 hours (25). Saberi et al. also have shown that maximum pain intensity is recorded within six hours after RCT (26). In the current study, naproxen showed a significant reduction in postoperative pain

level within the first 6 hours, in comparison with placebo. This finding may lead the clinicians to consider naproxen as a good analgesic after RCT.

The usual dosage range for commonly used naproxen in different studies has been 275- 550 mg (24). To minimize the side effects, we used the minimum dosage recommended by previous studies, though increasing the dose of naproxen would improve analgesic efficacy. However, future studies should attempt to evaluate different dose.

The presence of pre-treatment pain increases the chances for more severe postoperative pain (27). Considering this fact and because of the use of placebo in the current study, asymptomatic teeth with irreversible pulpitis were included in the present survey.

2% lidocaine with epinephrine 1/80,000 is one of the most frequently used anesthesia in endodontics. So, we used this form of analgesic agent in our study.

## Conclusion

According to the results of the present study, administration of naproxen after treatment reduced postoperative pain following root canal therapy. On the other hand, naproxen has the minimal cardiovascular side effects amongst NSAID's. Therefore, we recommend the prescription of naproxen as an analgesic after RCT, especially, in patients with cardiovascular problems. However, future studies with larger sample size and improved designs are necessary to illustrate the efficacy of naproxen on post-operative pain in endodontics.

## Acknowledgments

The authors wish to thank the Research Committee of Kerman University of Medical Sciences for financial support, and all the participants for their kind cooperation.

## References

1. Mehrvarzfar P, Abbott PV, Saghiri MA, Delvarani A, Asgar K, Lotfi M, et al. Effects of three oral analgesics on postoperative pain following root canal preparation: a controlled clinical trial. *Int Endod J*. 2012; 45:76–82.
2. Segura-Egea JJ, Cisneros-Cabello R, Llamas-Carreras JM, Velasco-Ortega E. Pain associated with root canal treatment. *Int Endod J*. 2009; 42(7):614-20.
3. Arias A, Azabal M, Hidalgo JJ, De la Macorra JC. Relationship between postendodontic pain, tooth diagnostic factors, and apical patency. *J Endod*. 2009; 35(2):189-92.
4. Seltzer S, Naidorf IJ. Flare-ups in endodontics: I. Etiological Factors. *J Endod*. 2004; 30(7):476-81.
5. Pochapski MT, Santos FA, de Andrade ED, Sydney GB. Effect of pretreatment dexamethasone on post-endodontic pain. *Oral Surg Oral Med Oral Pathol*. 2009; 108:790–5.
6. Parirokh M, Rekabi AR, Ashouri R, Nakhaee N, Abbott PV, Gorjestani H. Effect of occlusal reduction on postoperative pain in teeth with irreversible pulpitis and mild tenderness to percussion. *J Endod*. 2013; 39:1–5.
7. Keiser K, Hargreaves KM. Building effective strategies for the management of endodontic pain. *Endod. Topics*. 2002; 3: 93–105.
8. Huynh MP, Yagiela JA. Current concepts in acute pain management. *J Calif Dent Assoc*. 2003; 31(5):419-27.
9. Parirokh M, Sadr S, Nakhaee N, Abbott PV, Manochehrfar H. Comparison between prescription of regular or on-demand ibuprofen on postoperative pain after single-visit root canal treatment of teeth with irreversible pulpitis. *J Endod*. 2014; 40(2):151-4.
10. Niazi SK1, Alam SM, Ahmad SI. Dose dependent pharmacokinetics of naproxen in man. *Biopharm Drug Dispos*. 1996; 17(4):355-61.
11. Glennon JP, Ng YL, Setchell DJ, Gulabivala K. Prevalence of and factors affecting postpreparation pain in patients undergoing two-visit root canal treatment. *Int Endod J*. 2004; 37(1):29-37.
12. FitzGerald GA. COX-2 in play at the AHA and the FDA. *Trends Pharmacol Sci* 2007; 28(7):303-7.
13. Wells LK, Drum M, Nusstein J, Reader A, Beck M. Efficacy of ibuprofen and ibuprofen/acetaminophen on postoperative pain in symptomatic patients with a pulpal diagnosis of necrosis. *J Endod*. 2011; 37:1608–12.
14. Gottesdiener K, Mehlisch DR, Huntington M, Yuan WY, Brown P, Gertz B, Mills S. Efficacy and tolerability of the specific cyclooxygenase-2 inhibitor DFP compared with naproxen sodium in patients with postoperative dental pain. *Clin Ther*. 1999; 21:1301–12.
15. Woolf CJ, Chong MS. Preemptive analgesia--treating postoperative pain by preventing the establishment of central sensitization. *Anesth Analg*. 1993; 77(2):362-79.
16. Hass D. An update on analgesics for the management of acute postoperative dental pain. *J Can Dent Assoc*. 2002; 68(8): 476-82.
17. Saatchi M, Razavi M, Meskin M, Khoei M. Histopathologic study of the effect of celecoxib to control acute periapical inflammation after root canal treatment in cats. *Journal of Isfahan Dental School*. 2007; 2(4): 29-34.
18. Sanders D, Krause K, O'Muircheartaigh J, Thacker MA, Huggins JP, Vennart B, et al. Pharmacological modulation of hand pain in osteoarthritis: A double-blinded placebo-controlled functional magnetic

- resonance imaging study using naproxen. *Arthritis Rheumatol.* 2014 Dec 22.
19. Azouble MCF, Menezes AMA, Riberio RA. Comparison of Etoricoxib and Indomethacin for the treatment of experimental periodontitis in rats. *Braz J Med Bio Res.* 2007; 40(2): 117-25.
  20. Goyal A, Mansel RE. A randomized multicenter study of gamolenic acid (Efamast) with and without antioxidant vitamins and minerals in the management of mastalgia. *Breast J.* 2005; 11: 41-7.
  21. Gateley CA, Miers M, Mansel RE, Hughes LE. Drug treatments for mastalgia: 17 years experience in the Cardiff mastalgia clinic. *J R Soc Med.* 1992; 85: 12-5.
  22. Polat O, Karaman A, Durmus E. Effects of preoperative Ibuprofen and Naproxen on orthodontic pain. *Angle Orthod.* 2005; 75(5): 791-6.
  23. Frike J, Morrison MW, Fite S. MMK-966 versus Naproxen Sodium 550 mg in post surgical dental pain. *Clin Pharmacol.* 1999; 65(5):119-25.
  24. Bjornsson GA, Haanaes HR, and Skoglund LA. Naproxen 500 mg bid versus acetaminophen 1000 mg qid: effect on swelling and other acute postoperative events after bilateral third molar surgery. *J Clin Pharmacol.* 2003; 43(8):849-58.
  25. Saatchi M, Mosavat F, Razmara F, Soleymani B. Comparison of the effect of Ibuprofen and slow-released Diclofenac Sodium in controlling post endodontic pain. *JDM.* 2009; 22(4): 185-91.
  26. Saberi EA, Hosseini-Goosheh M, Mirkahnooj R, Ansari H. A comparative study between the efficacy of tramadol, celecoxib and ibuprofen in pain control after root canal therapy of tooth. *ZJRMS.* 2011; 12(5): 79-83.
  27. Torabinejad M, Kettering JD, McGraw JC, Cummings RR, Dwyer TG, Tobias TS. Factors associated with endodontic interappointment emergencies of teeth with necrotic pulps. *J Endod.* 1988; 14(5):261-6.